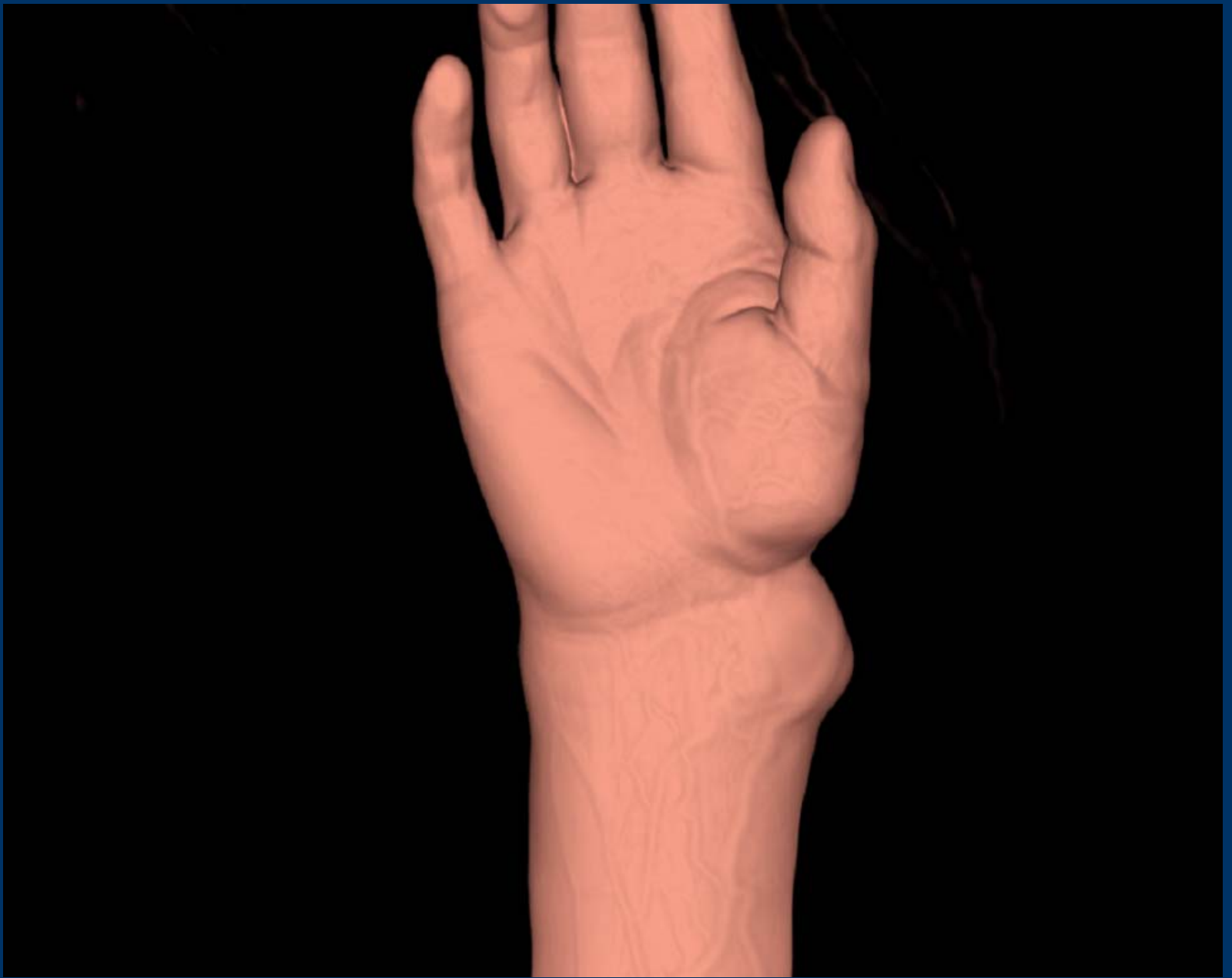
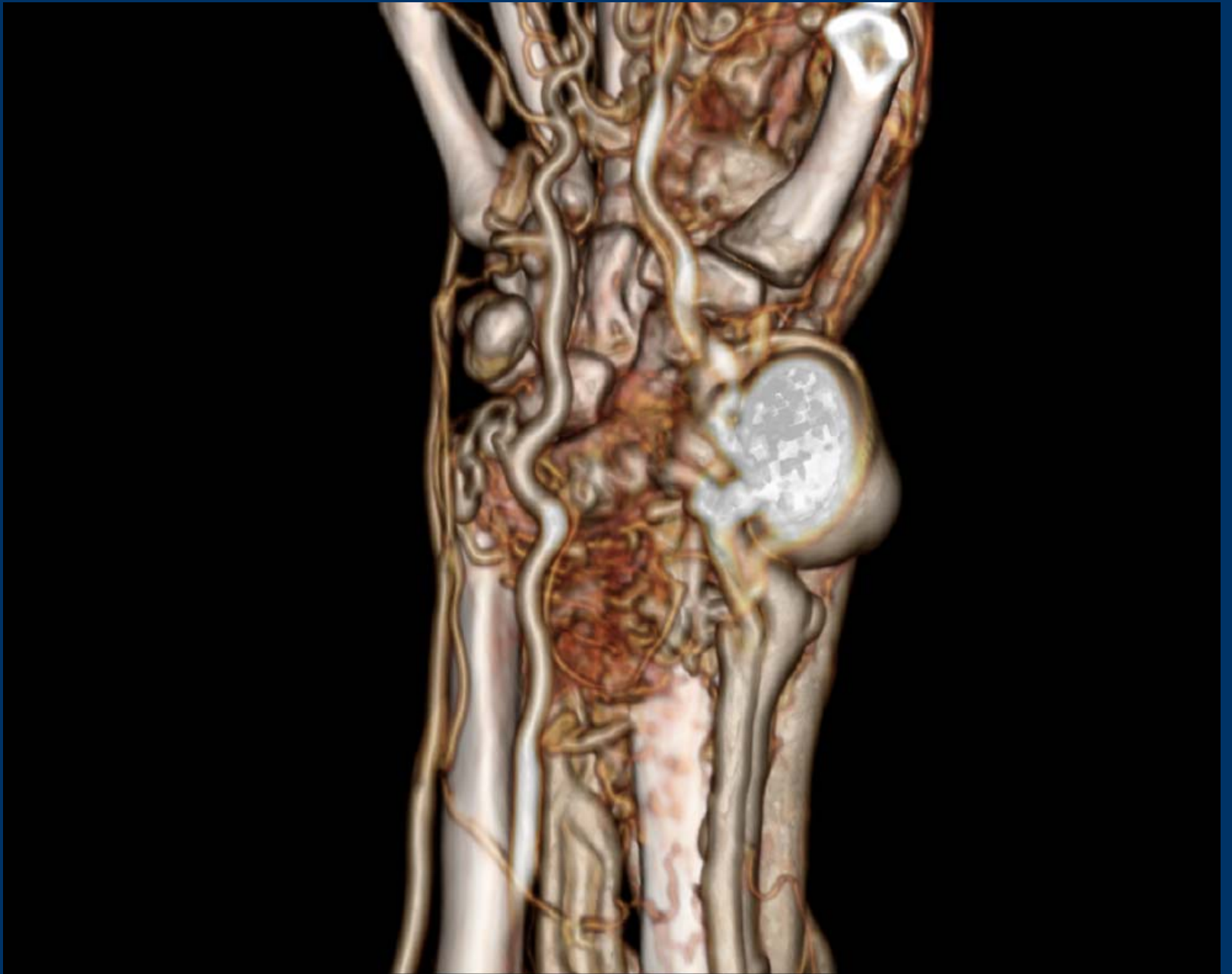

VD is a 26 yo male with a long history (> 10 yrs) of having a RUE arteriovenous malformation. Noted to have an increasing R radial artery aneurysm. Unsuccessful attempt at embolization of his AVM in 2007 at UCSF. Increasing size of his aneurysm has caused difficulty with writing and activities requiring wrist flexion.







Volume Rendering No cut

Ex: Feb 06 2008

DFOV 35.0 cm  
SOFT/+

Right

R  
2  
0  
6

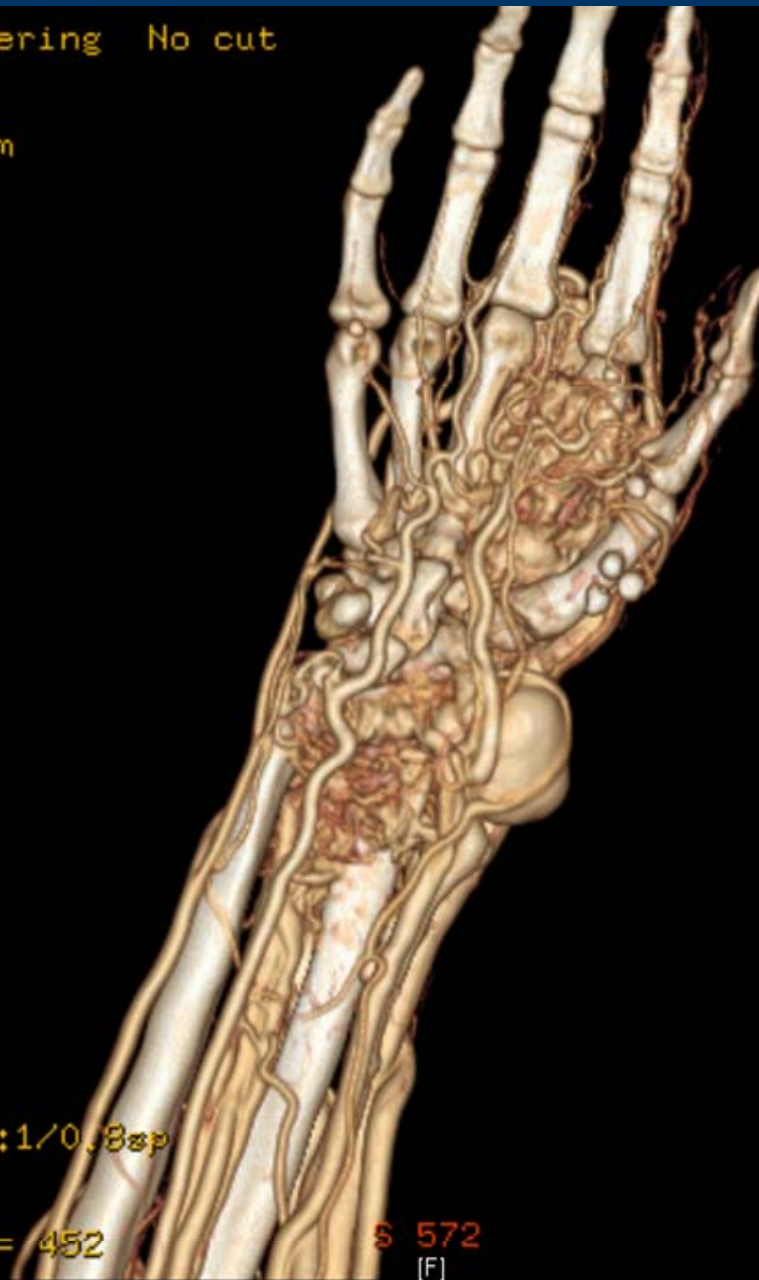L  
1  
4  
4

No VOI

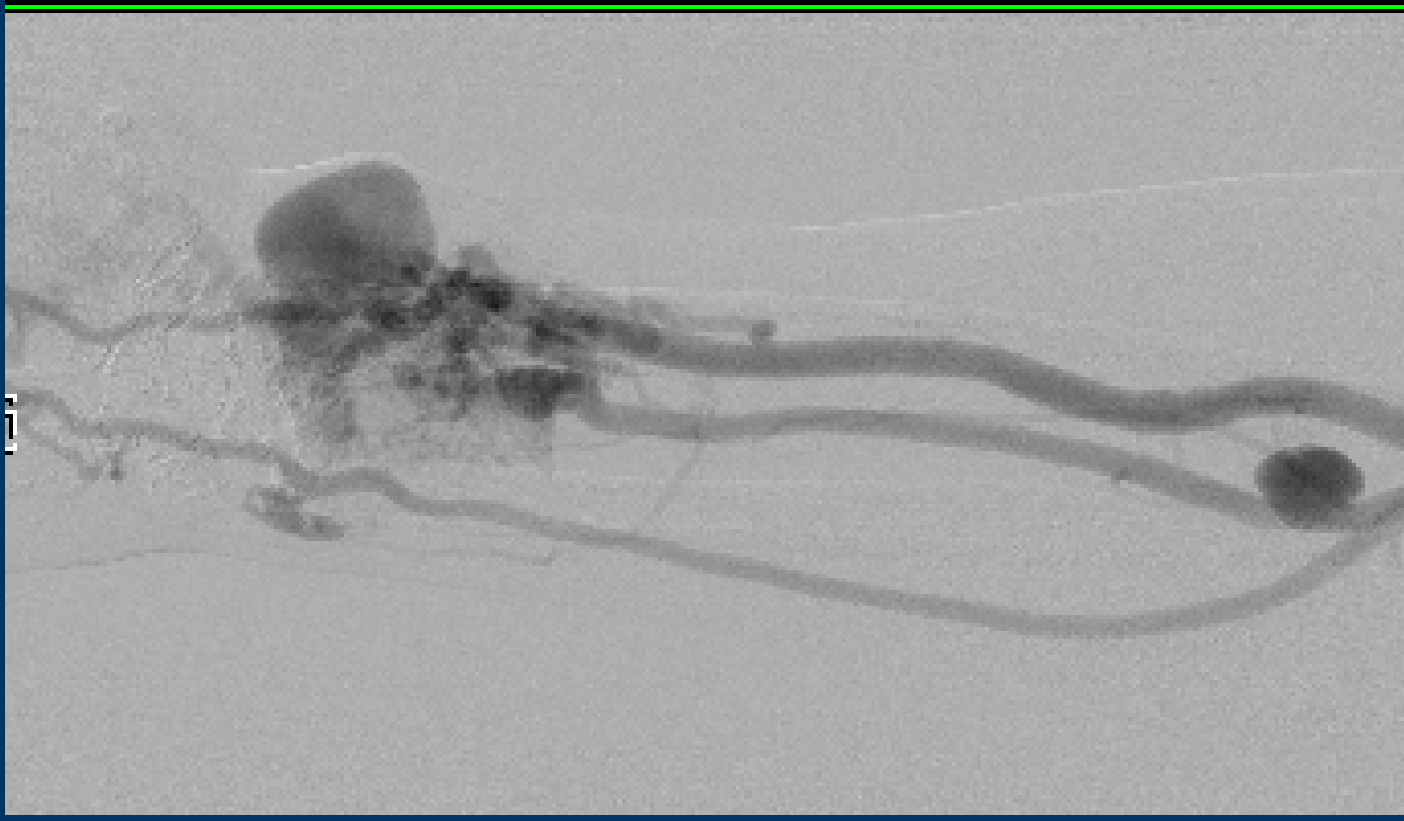
1.2mm 1.375:1/0.8sp

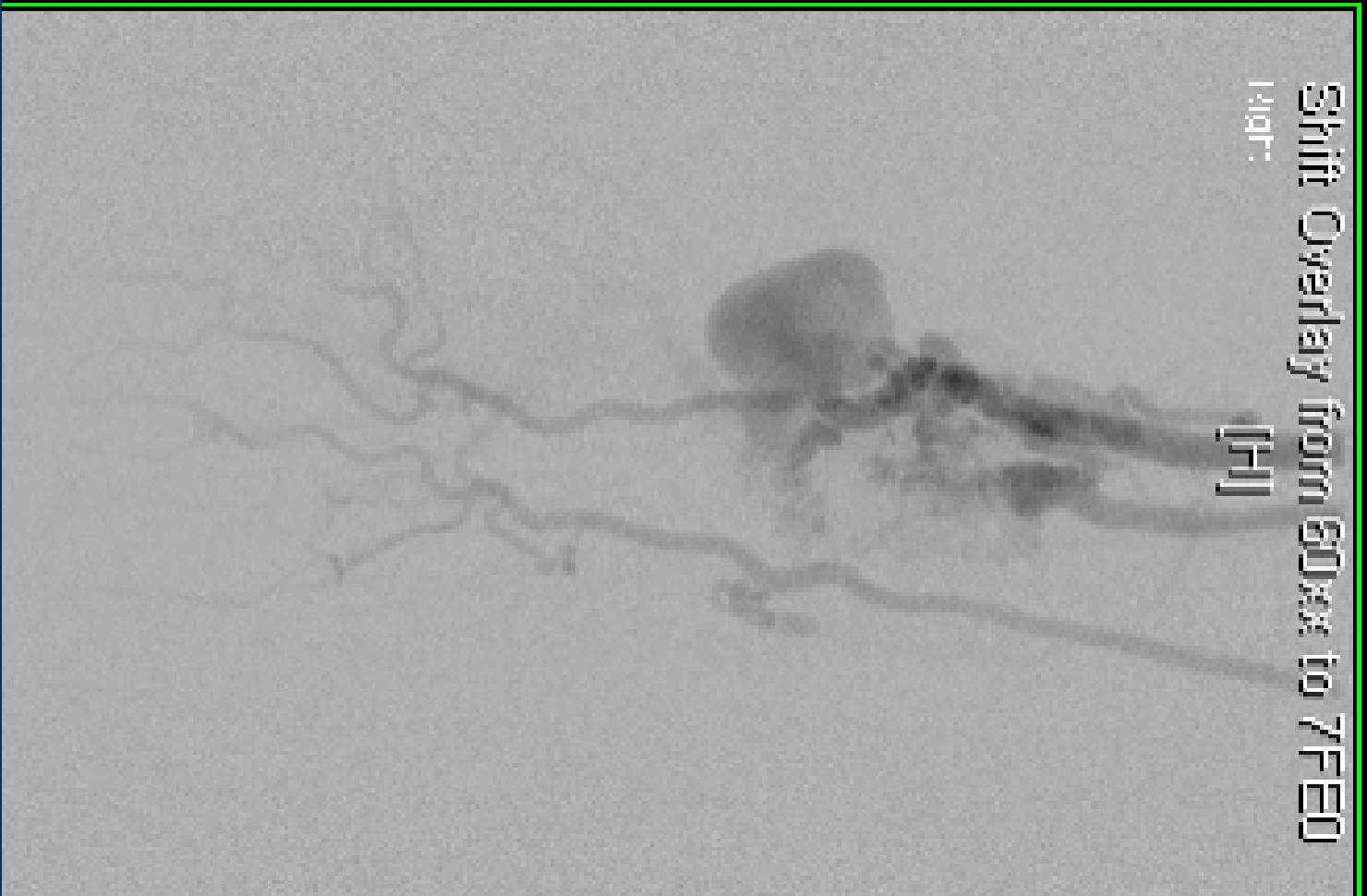
W = 1071 L = 452

S 572  
[F]



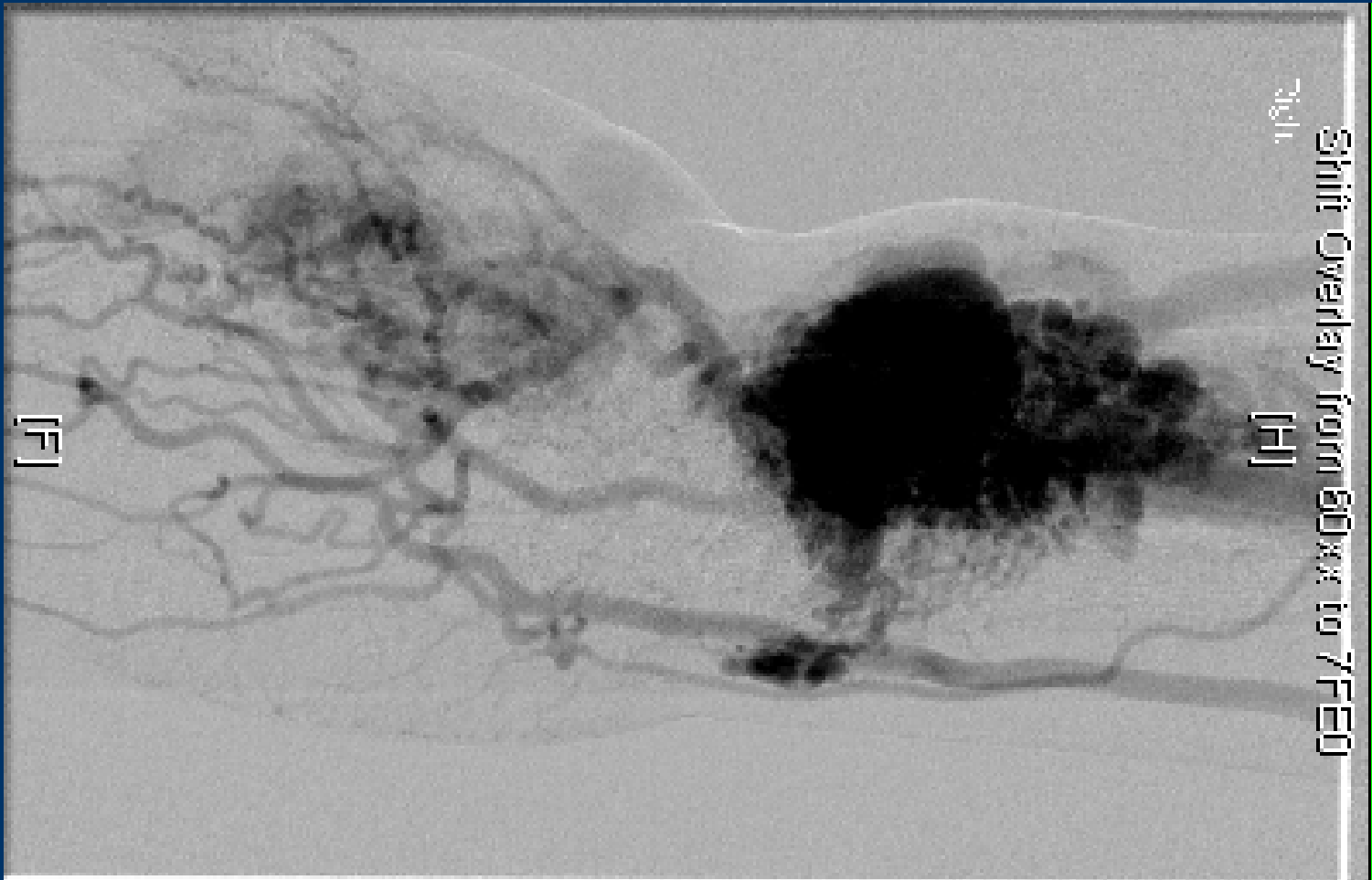
Shift Overlay from 80x to 7FE0  
[H]





Shift Overlay from 80kV to 7FEO  
[H]

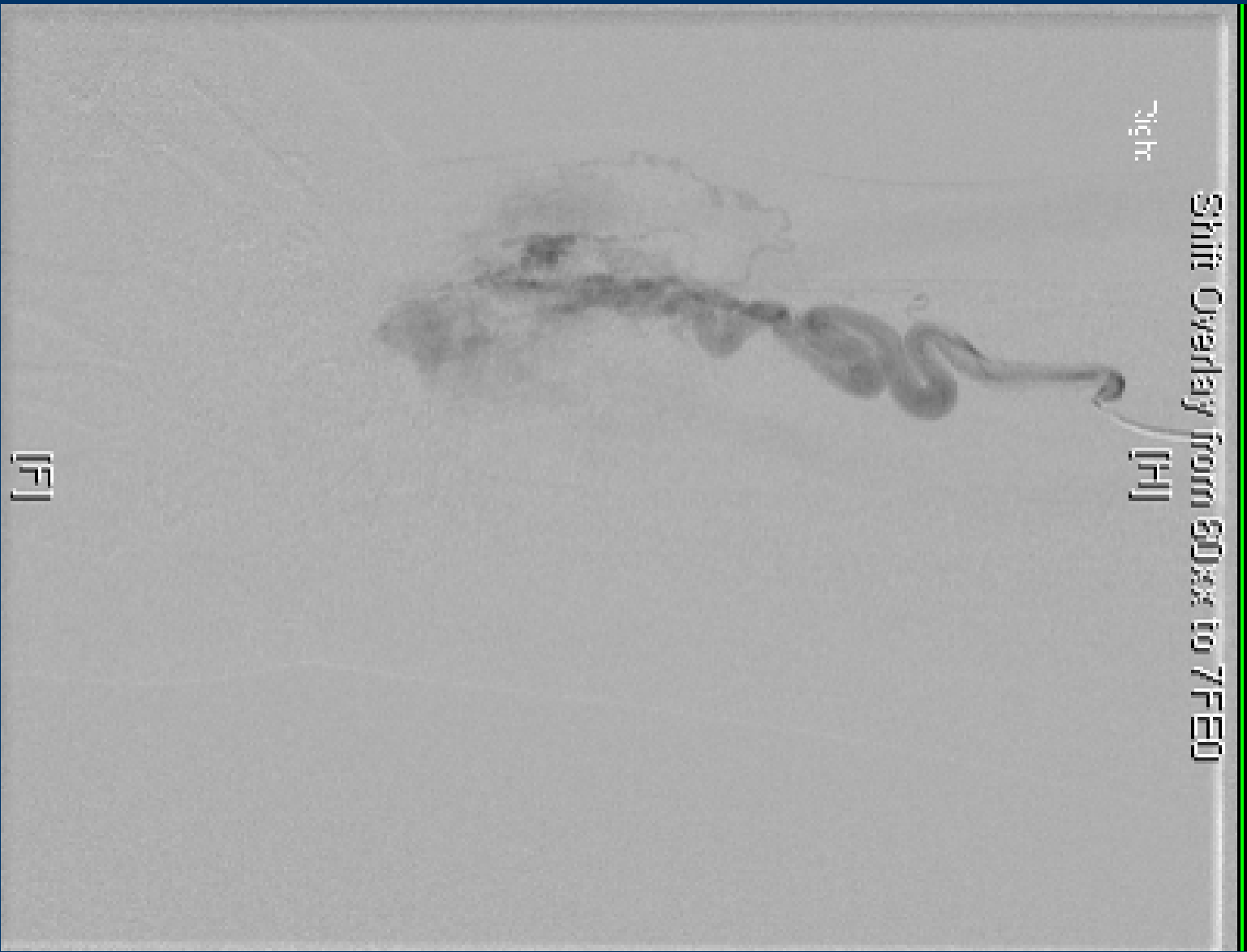




Shift Overlay from 800K to 7FE0  
High

[F]





Right

Shift Overlay from 60 kVp to 75 kVp

[H]

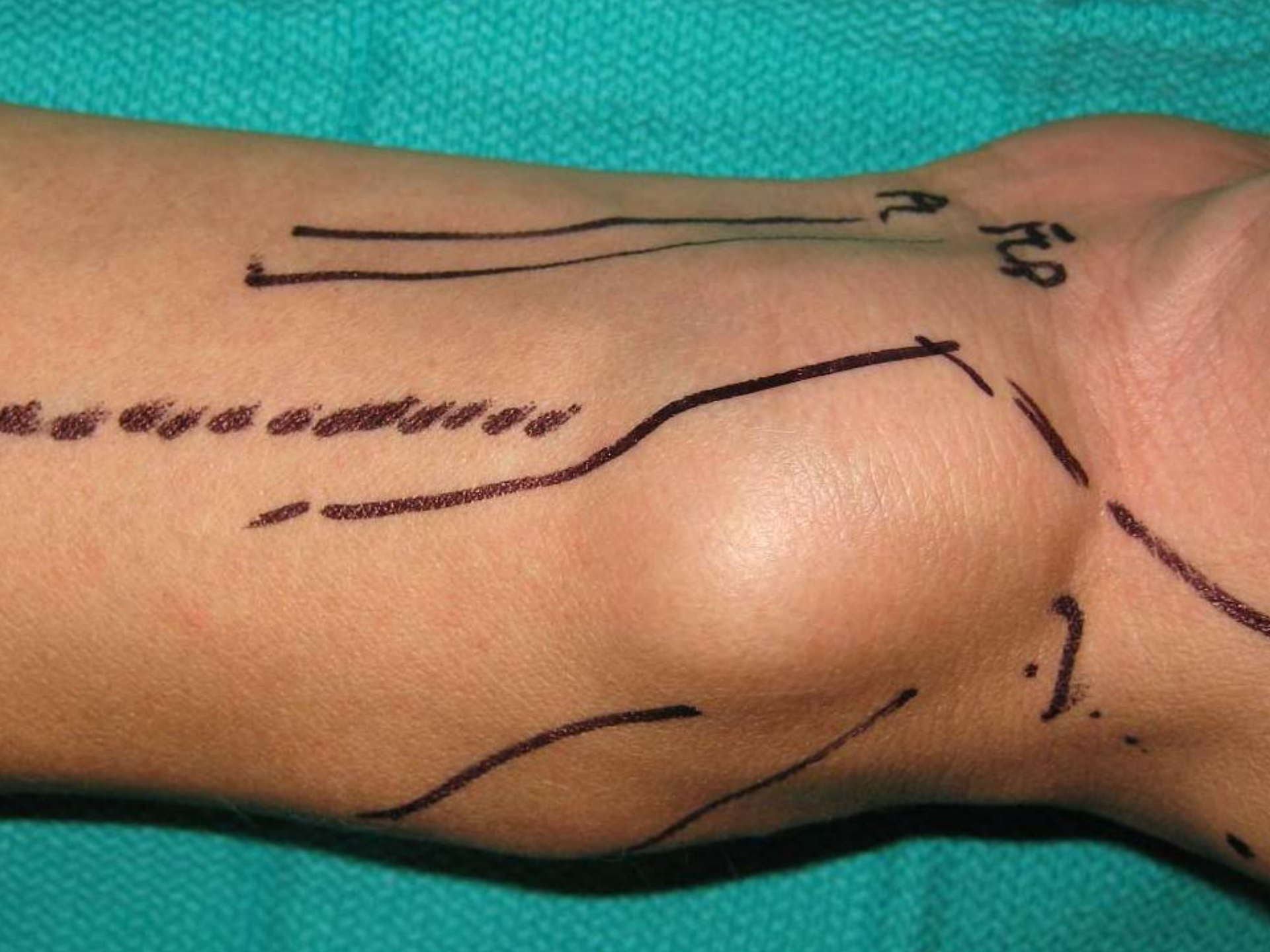
[F]





# Treatment options?



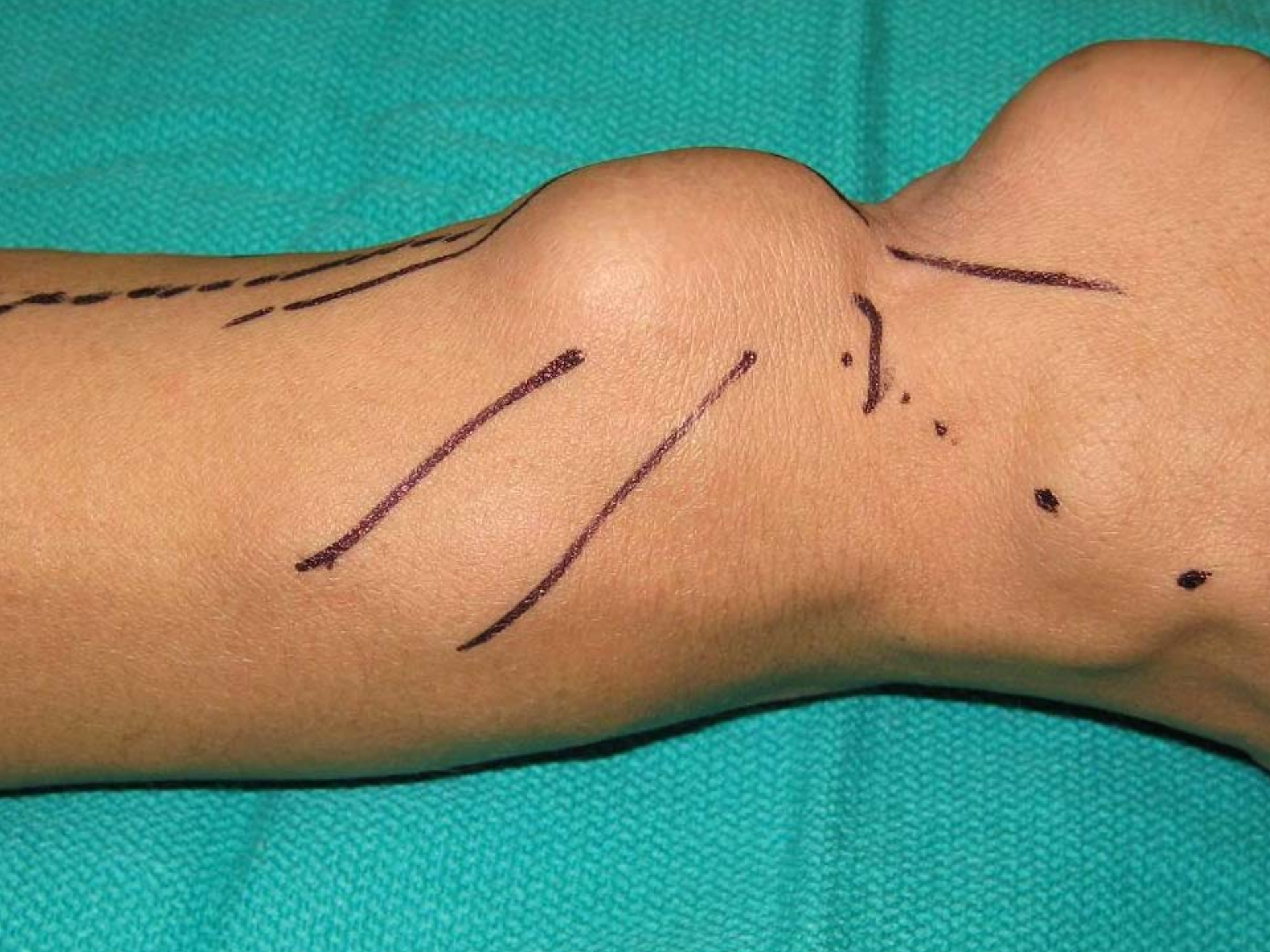

R

FUR

Scalloped surgical marking





# Resection of Right radial artery aneurysm and repair with interposition SVG





