

GG is a 61 yo m with a R abdominal mass x 1 month. Presented with R-sided abdominal pain that gradually became worse. Developed bilateral lower extremity edema x 3 weeks. Workup revealed a complex R abdominal mass of fatty component extending into the inferior vena cava.



# Medical History

HTN

Hyperlipidemia

Chronic lower back pain



## Physical exam:

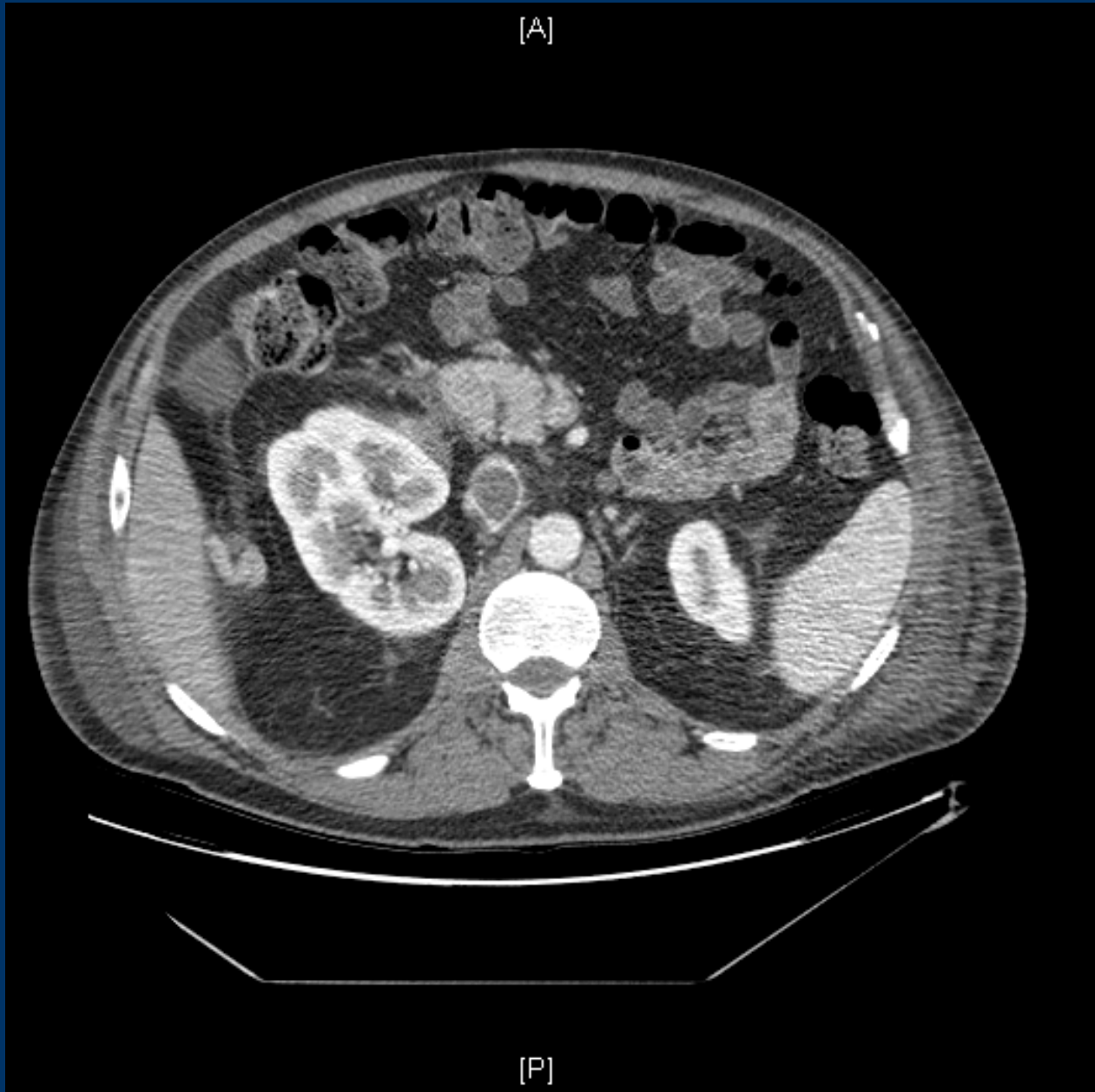
- Palpable, firm R abdominal mass
- B 2+ fem pulses and distal pulses
- B 2+ pedal edema

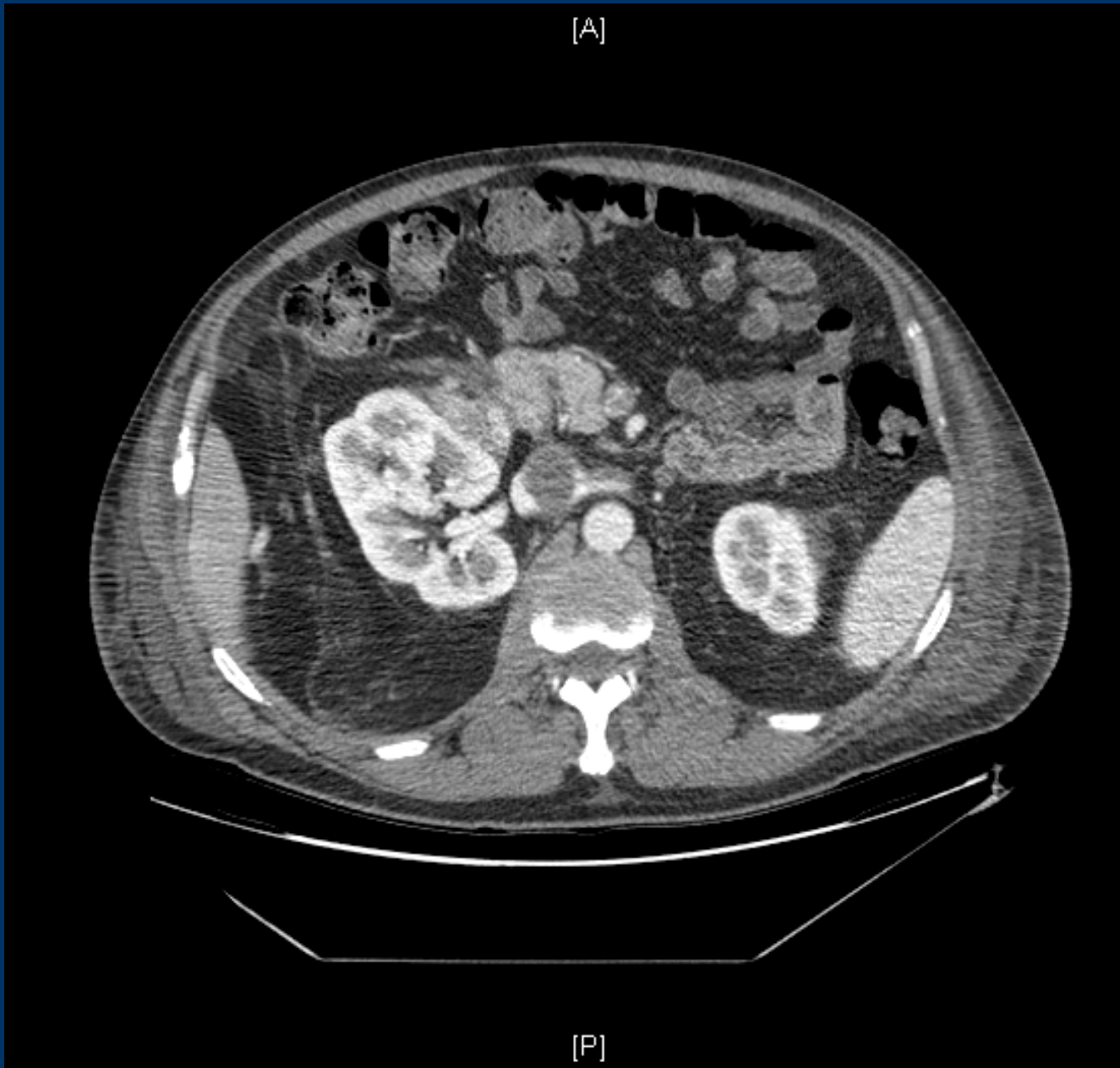


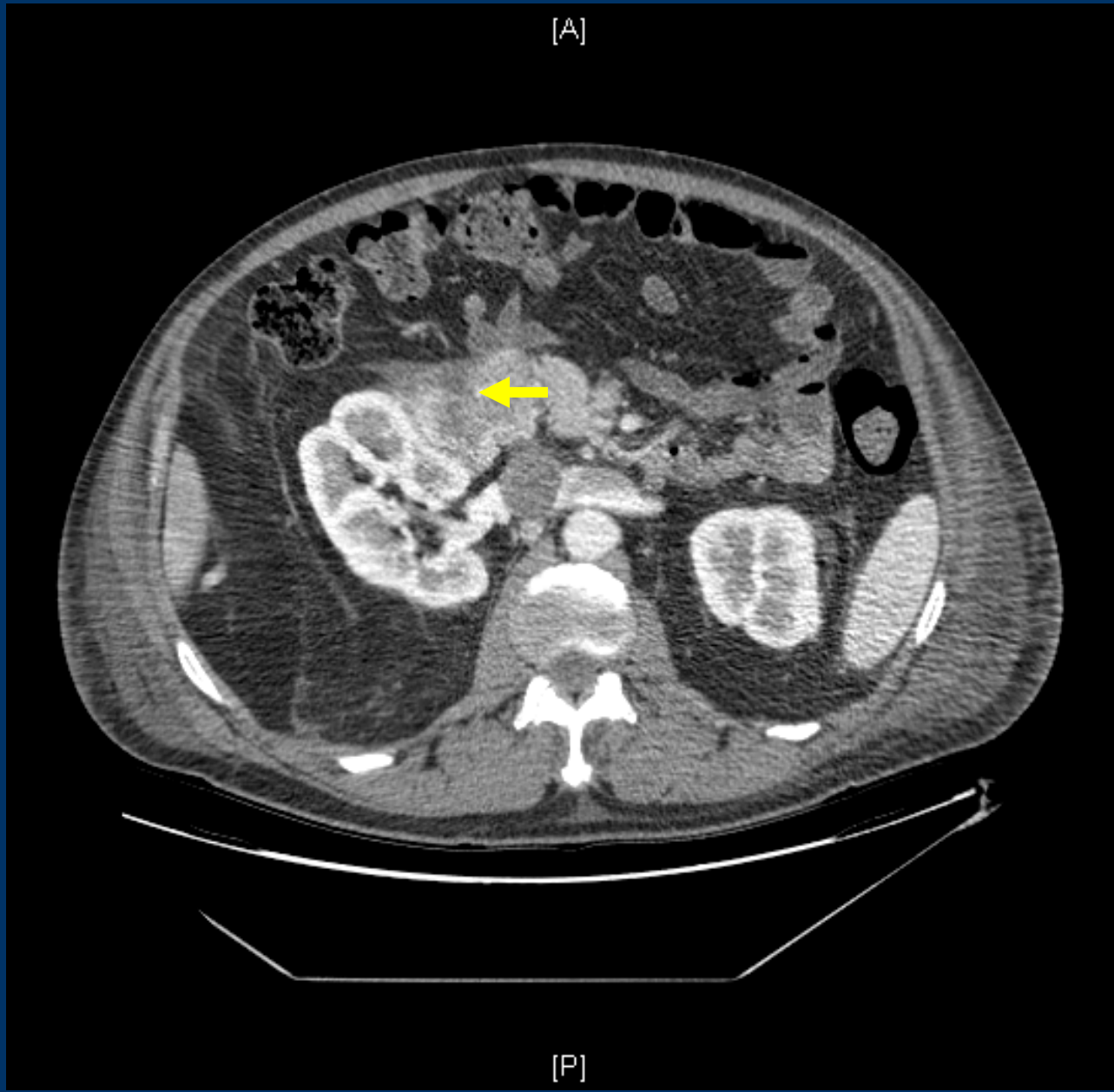
## CT angio (10/4/07):

- Large heterogeneous right retroperitoneal mass with mixed attenuation encasing the right kidney. Mass measures 16 x 18 x 29 cm and extends to the abdominal wall (laterally) and possibly invades the pancreatic head and duodenum (medially).
- There is invasion of the infrarenal inferior vena cava by the enhancing soft tissue mass component, with filling defects seen from immediately suprarenal within the inferior vena cava to the bilateral common iliac veins. There appears to be filling-defect in the right external iliac vein and right common femoral vein.

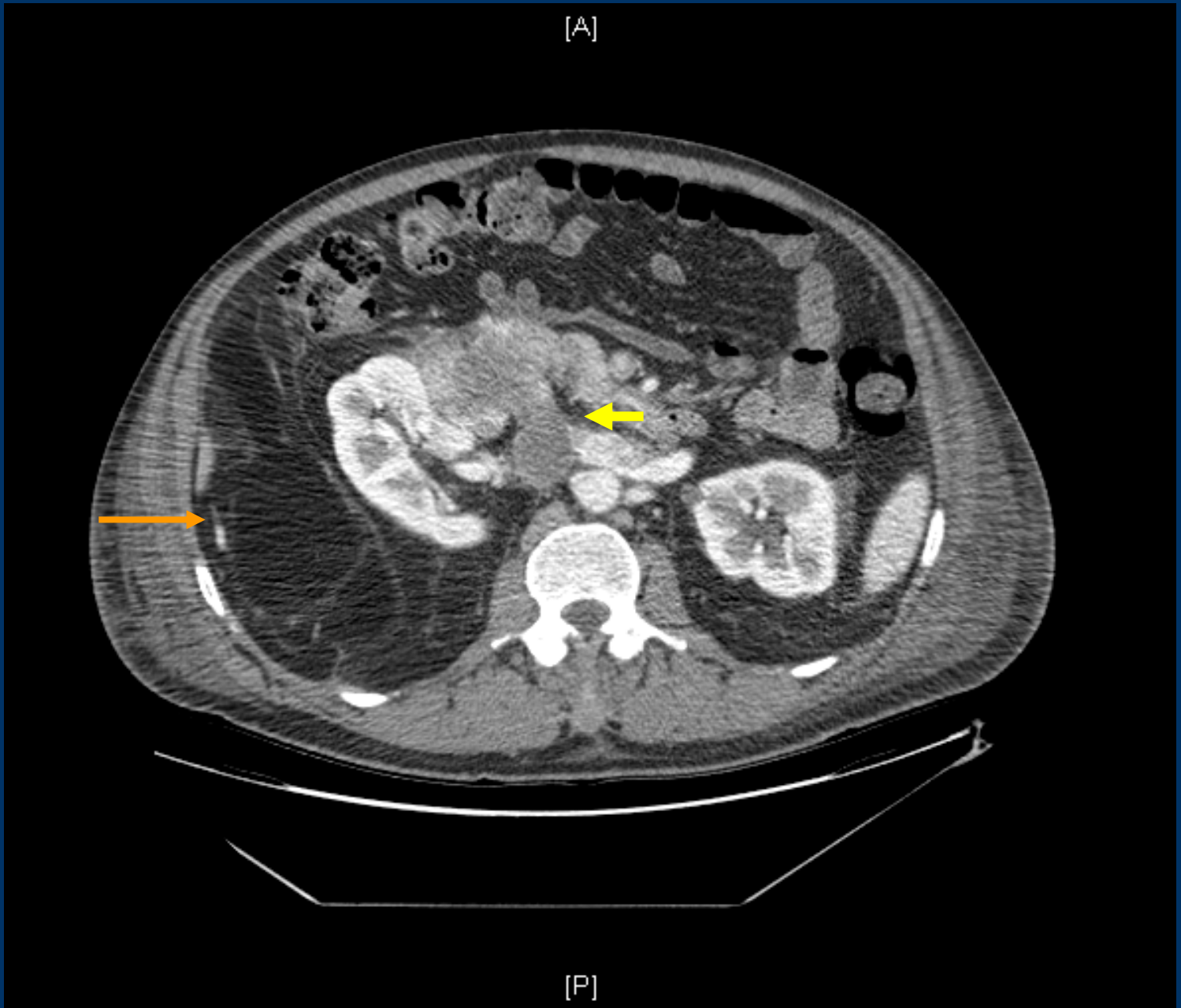






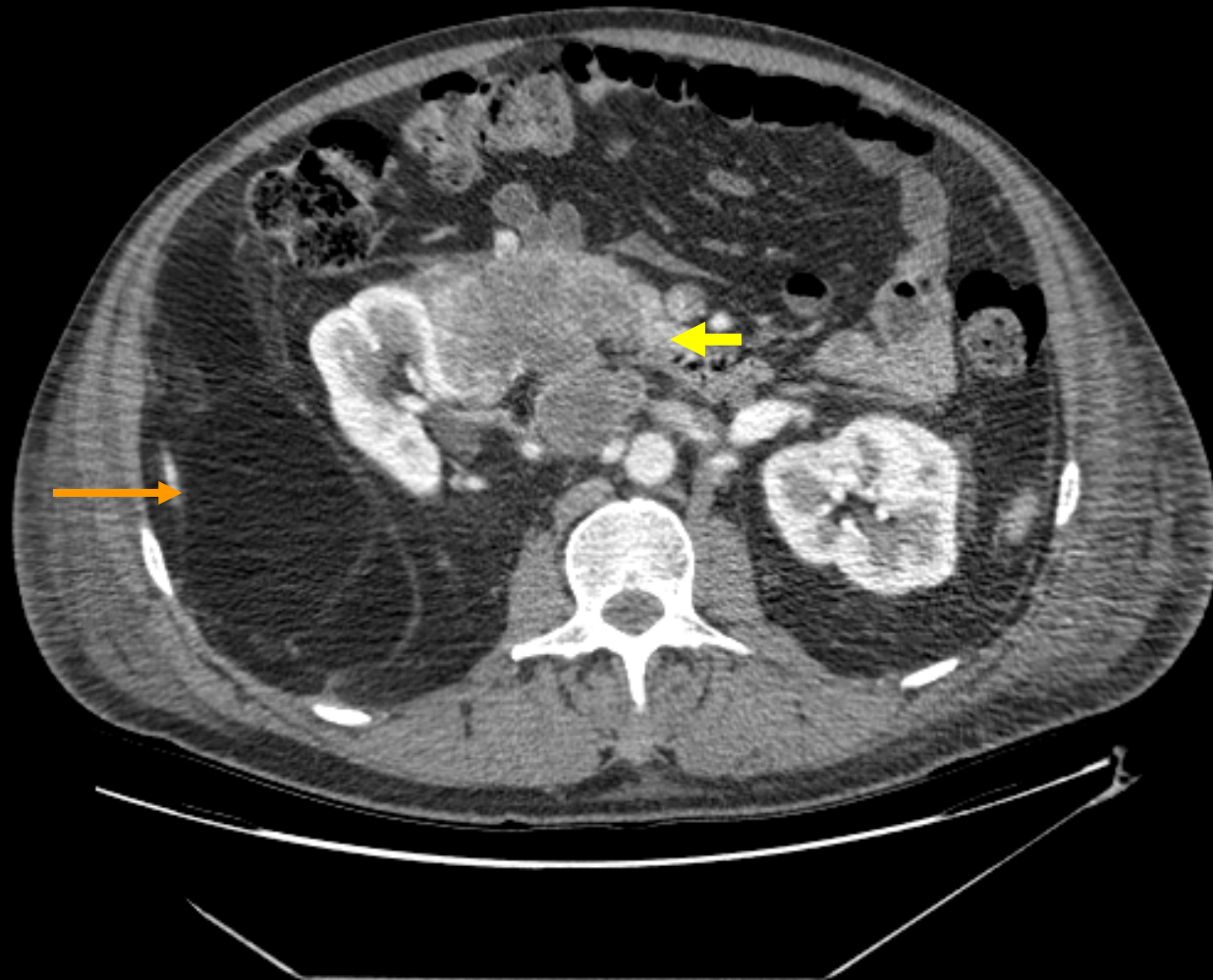






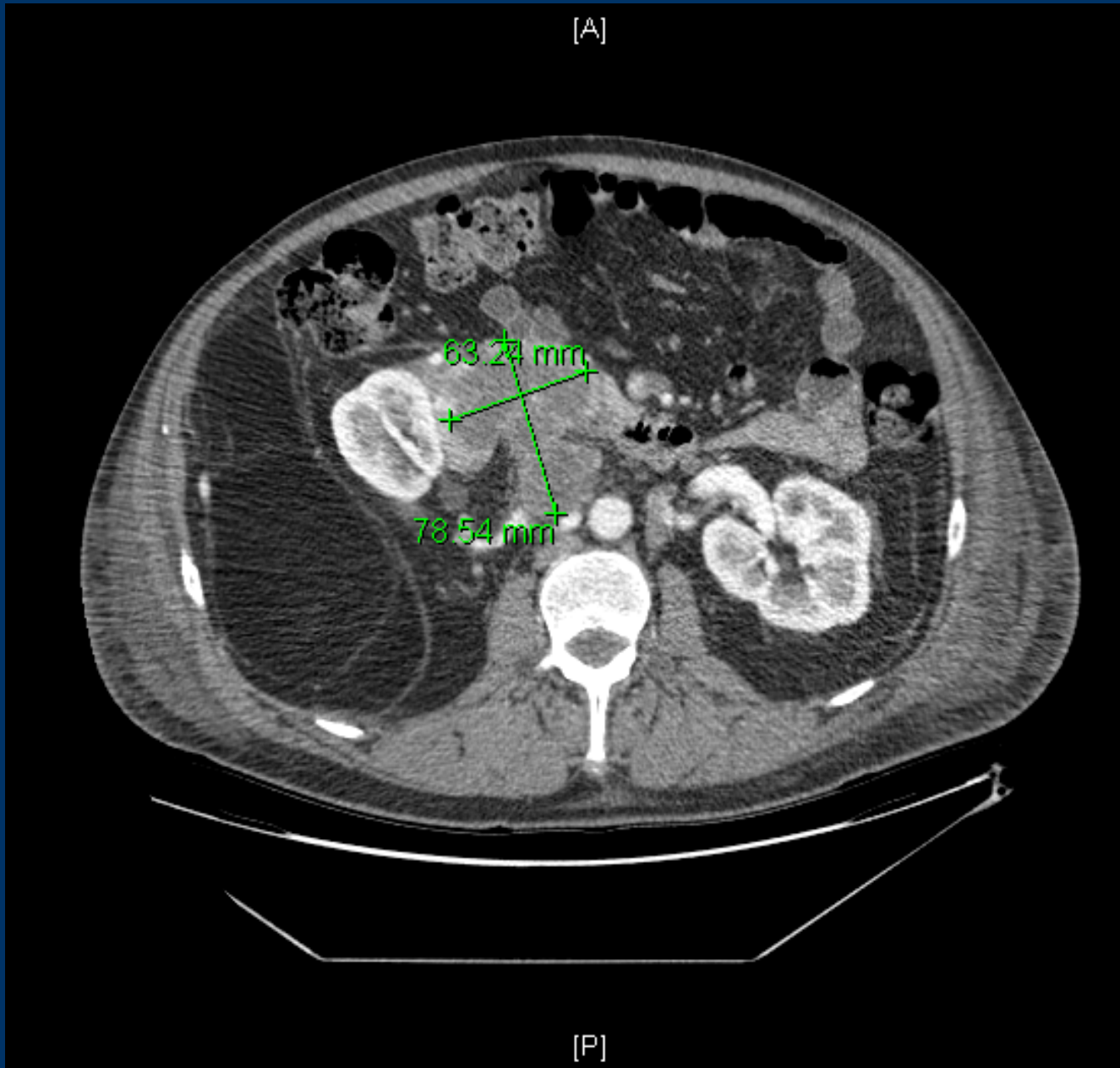


[A]

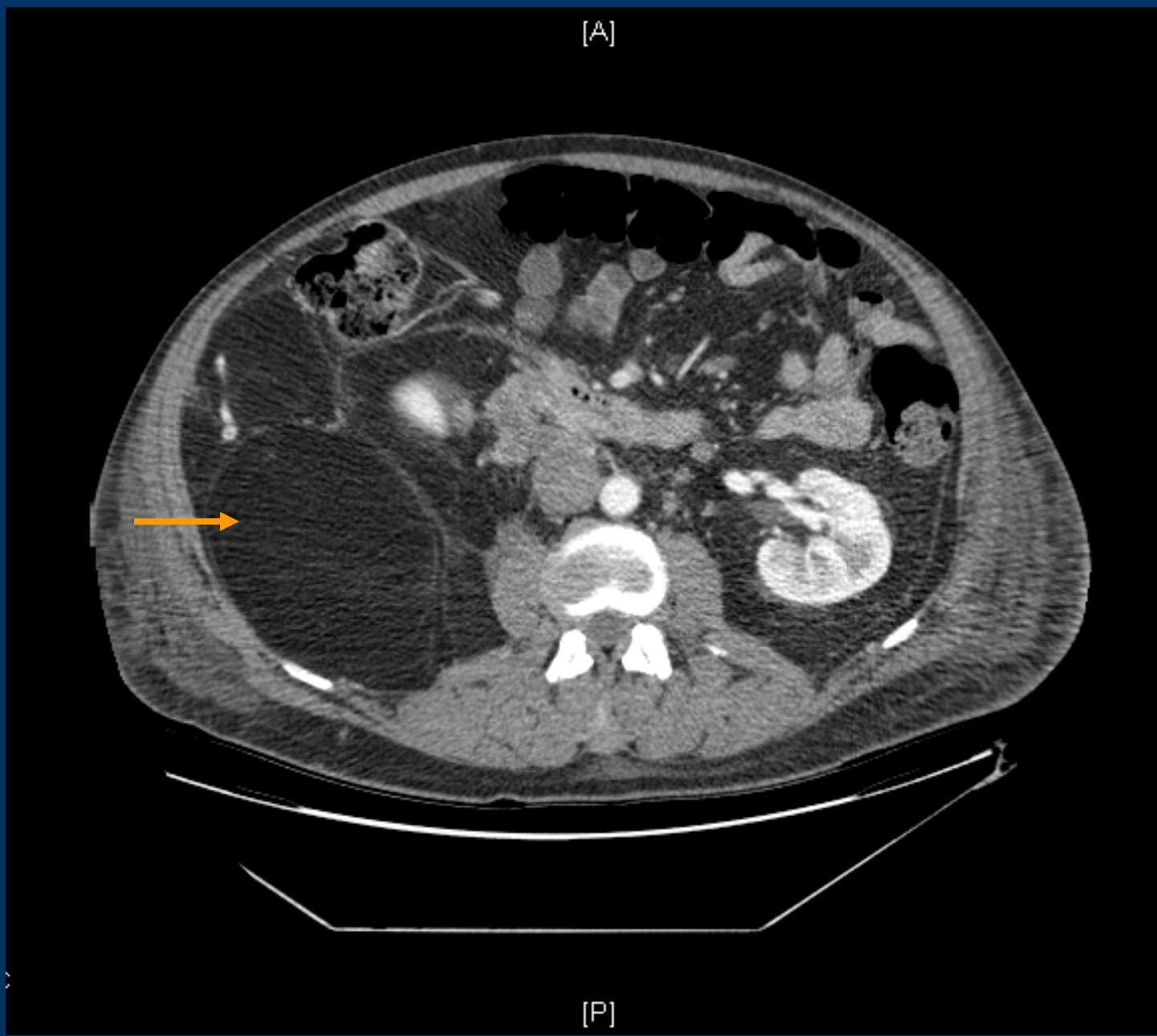


[F]





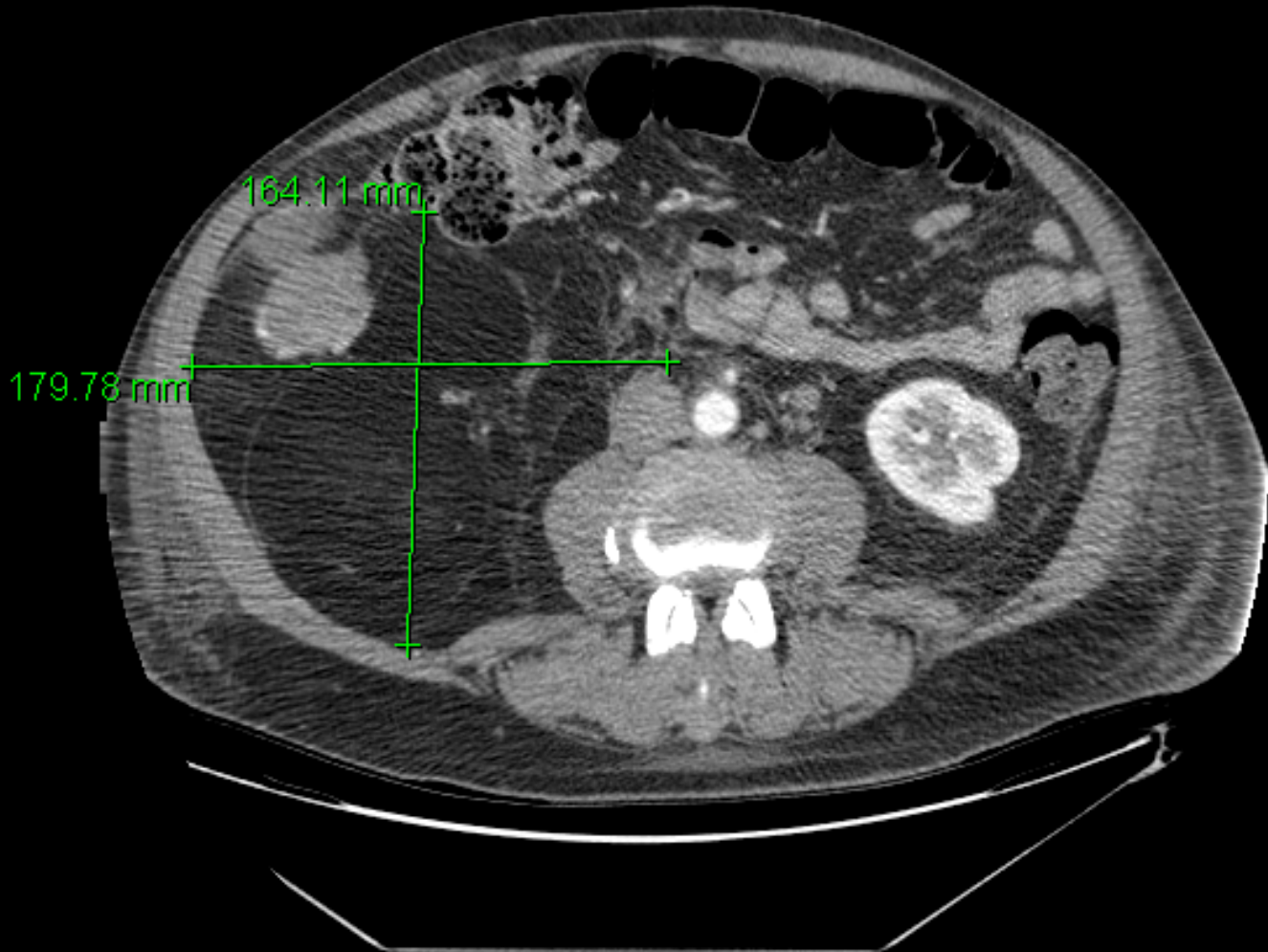[A]



[P]



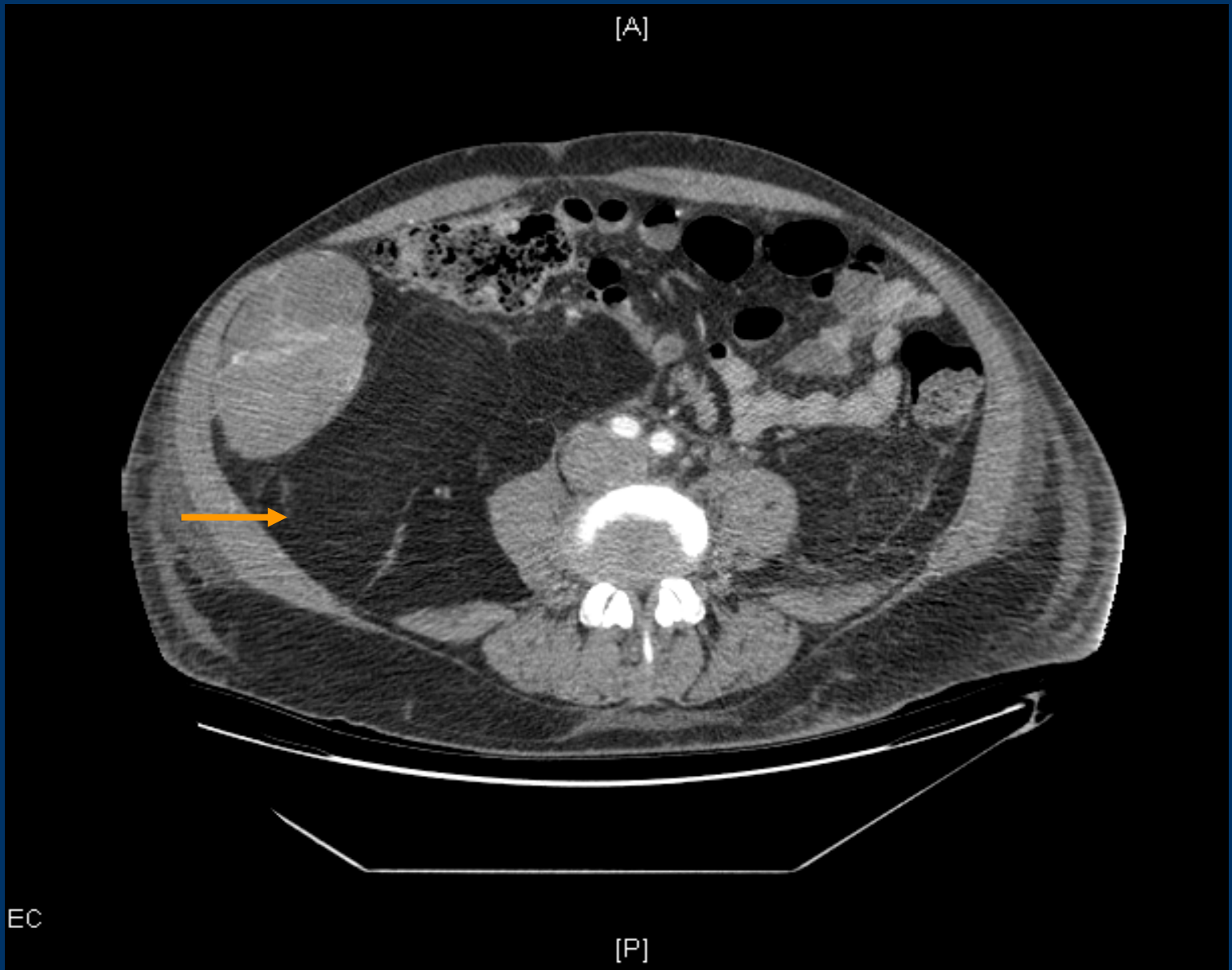
[A]



SEC

[P]







Curved  
Ex: 4332  
Se: 13 +c  
Angle: 0.0

ET:1

R IVC/ RT  
iliac vein IVC →  
cpr

320X224/0.78 NEX  
00:25  
0.9/1.8sp  
DFOV 34.5 cm  
HD BodyFull  
TI:8  
EC:1/1 62.5kHz  
TE:2.1/  
TR:4.4  
RM/SIGNA HDx 1.5T  
SAT\_GEMS\EDR\_GEMS\PPF\FS

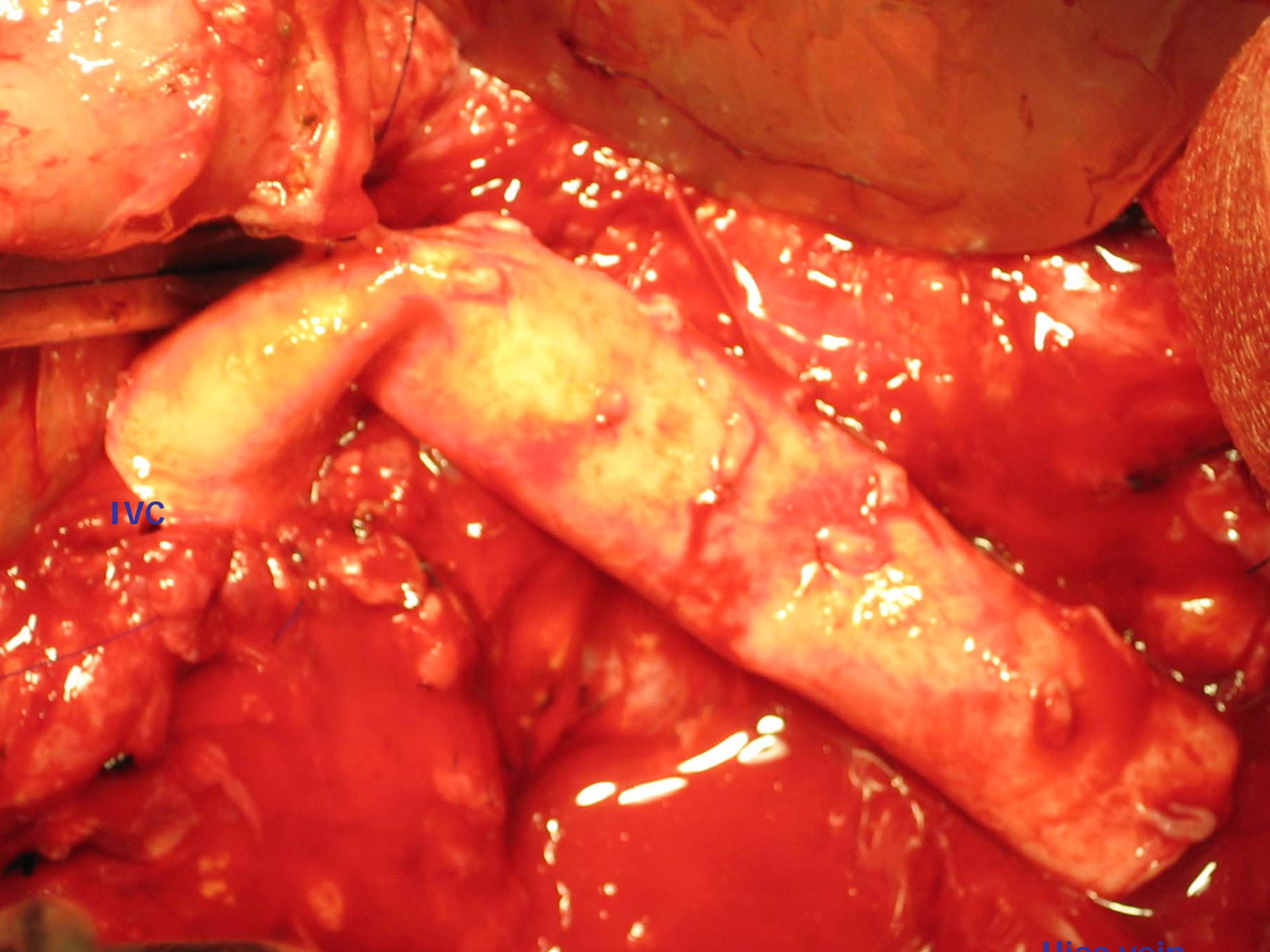
I



# Options?



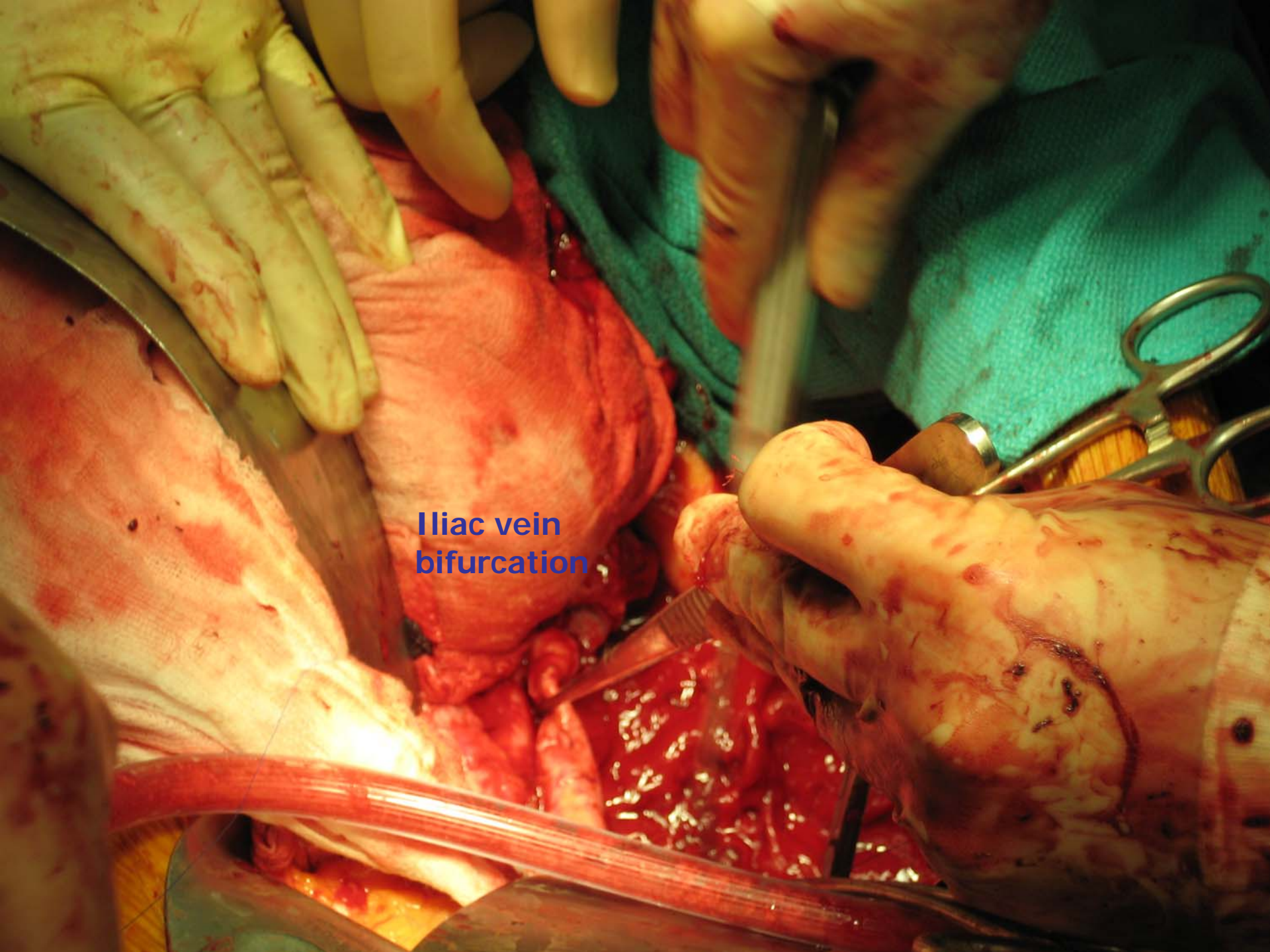




IVC

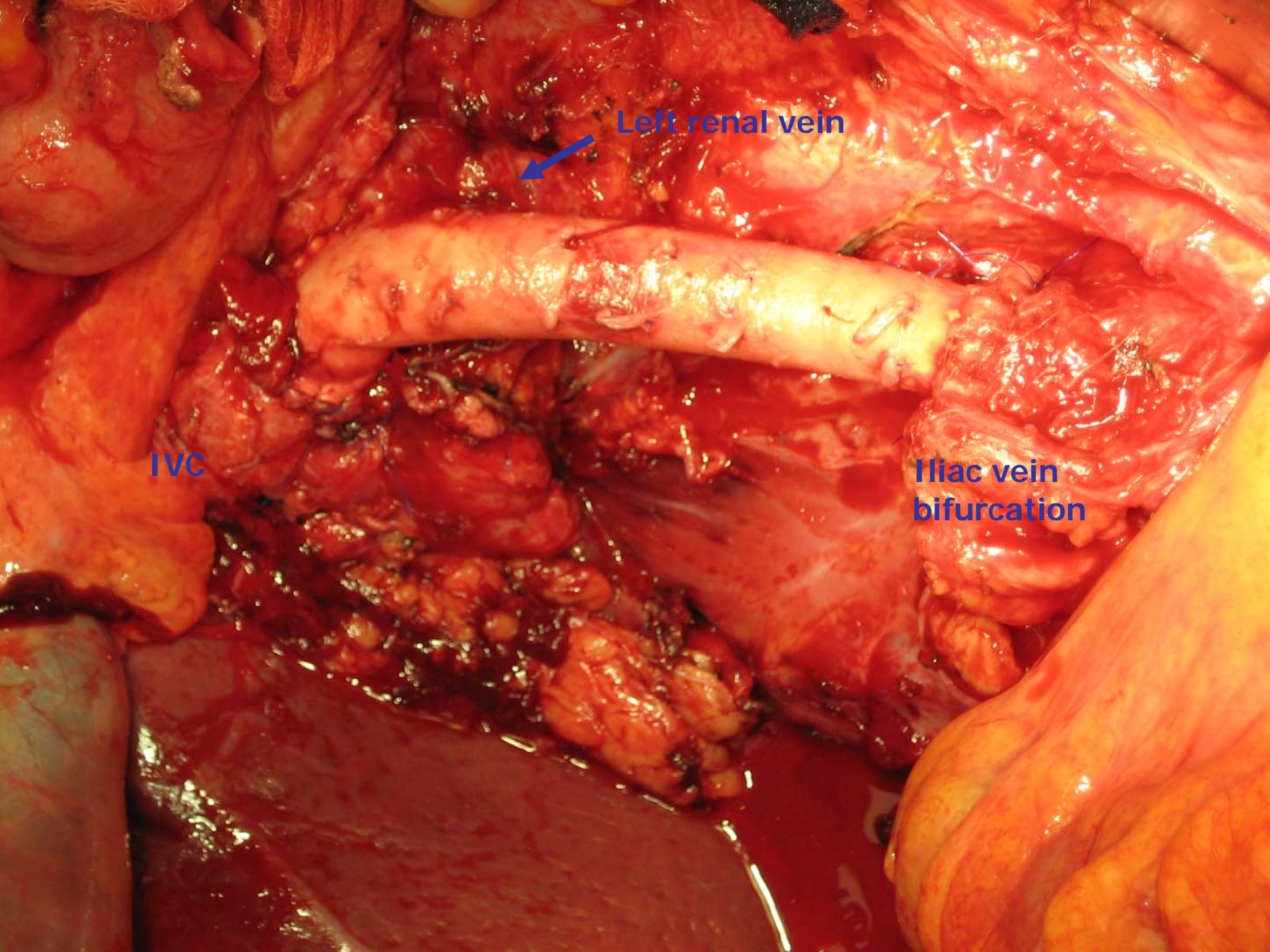
Iliac vein





Iliac vein bifurcation





Left renal vein



IVC

Iliac vein bifurcation