

VB is a 60 yo female c/o right back pain.
Workup revealed a right renal artery
aneurysm measuring 2.5 cm. Normal
creatinine of 1.0



Medical History

HTN

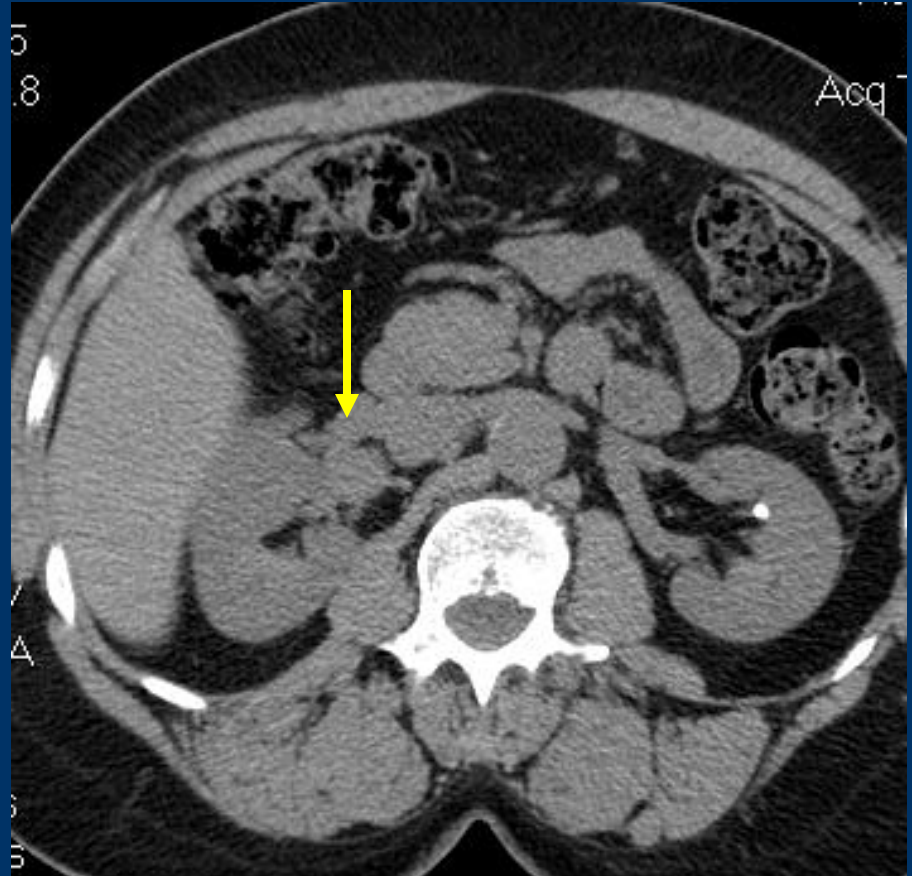
Hyperlipidemia

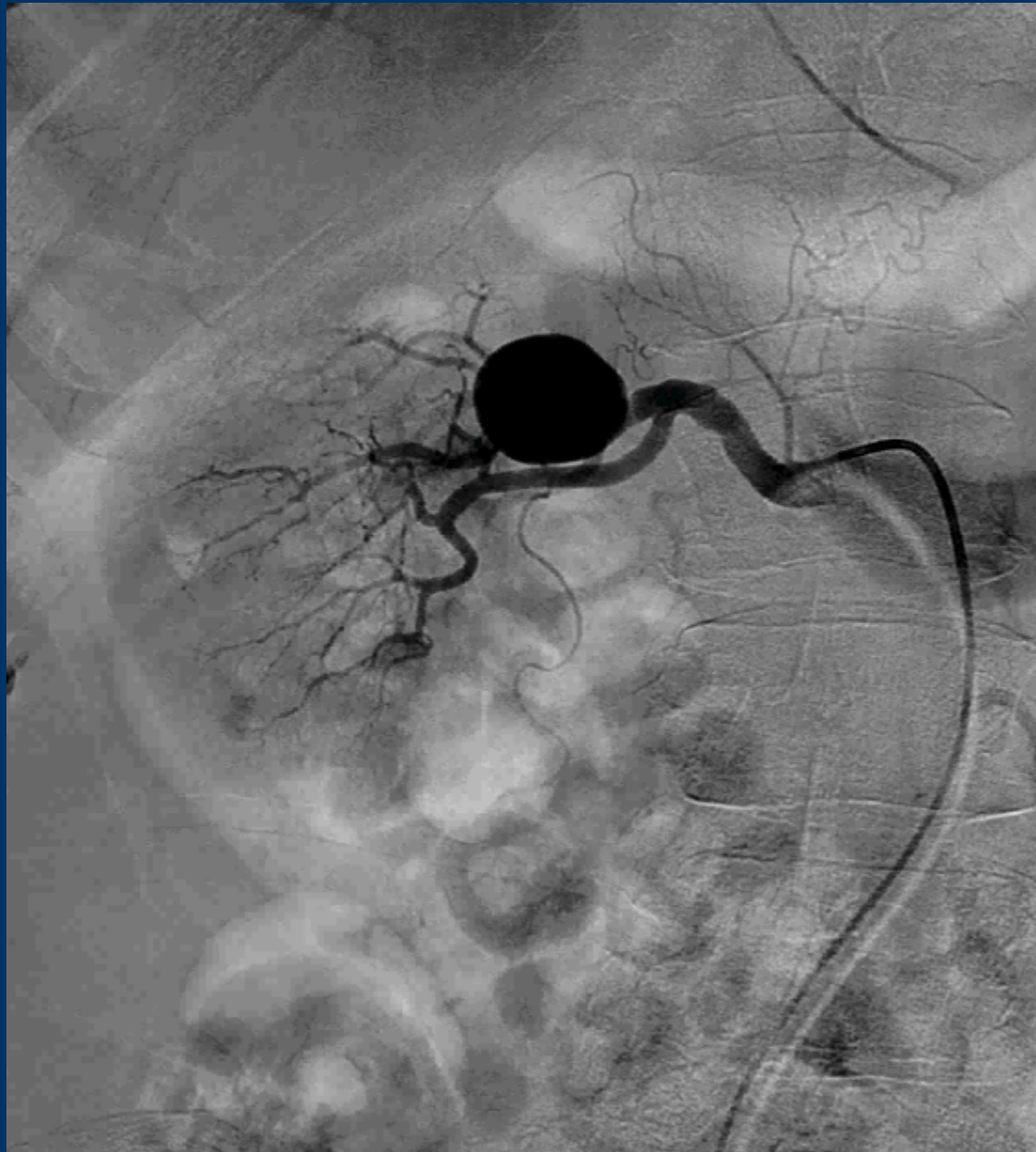s/p appendectomy

s/p C-section



- Right Renal artery aneurysm (~2 cm)
- Creatinine 1.0





Vascular Surgery



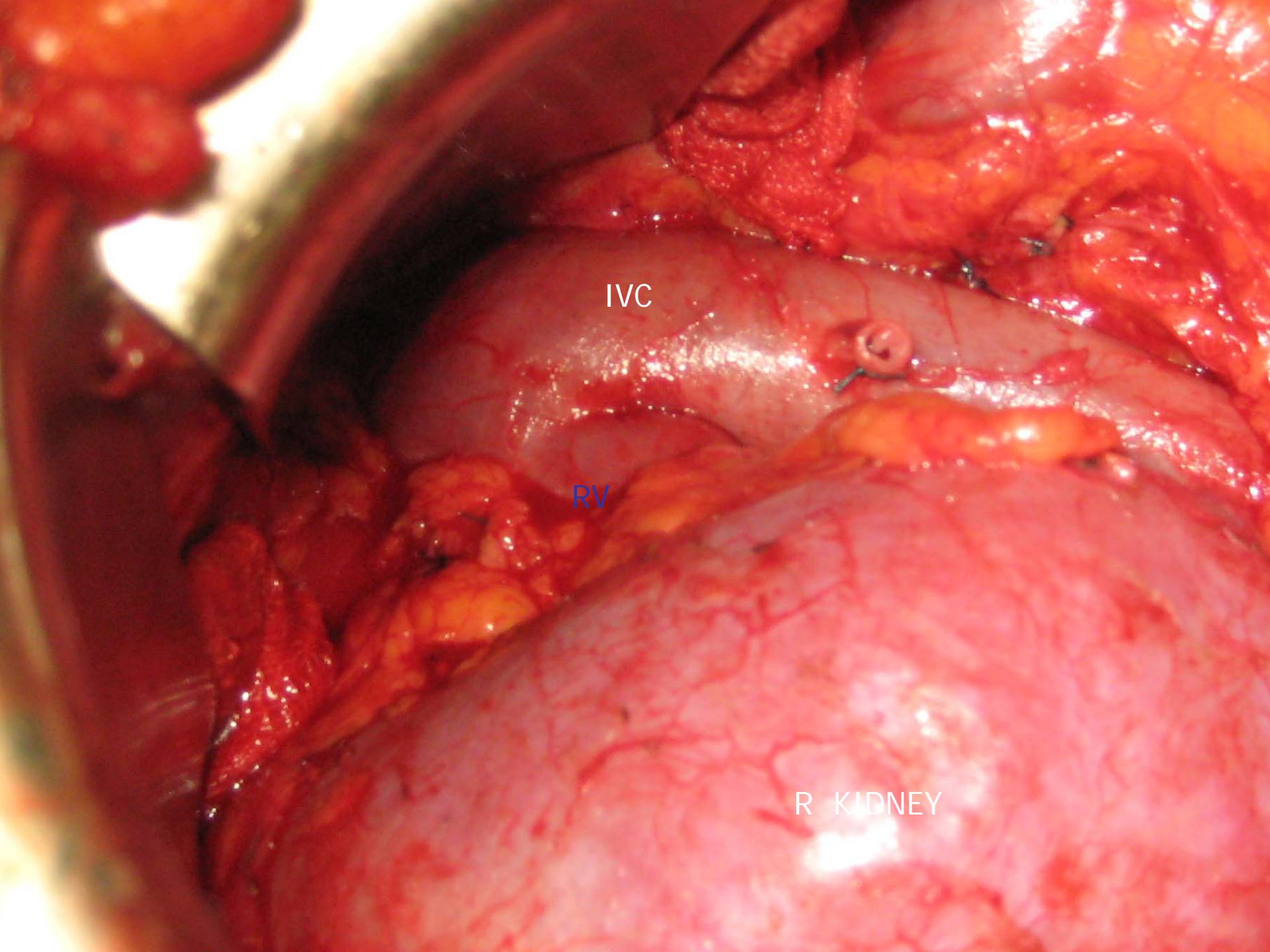
Treatment Options?



Operation:

Ex-vivo Right renal artery
aneurysm repair with vein patch
angioplasty

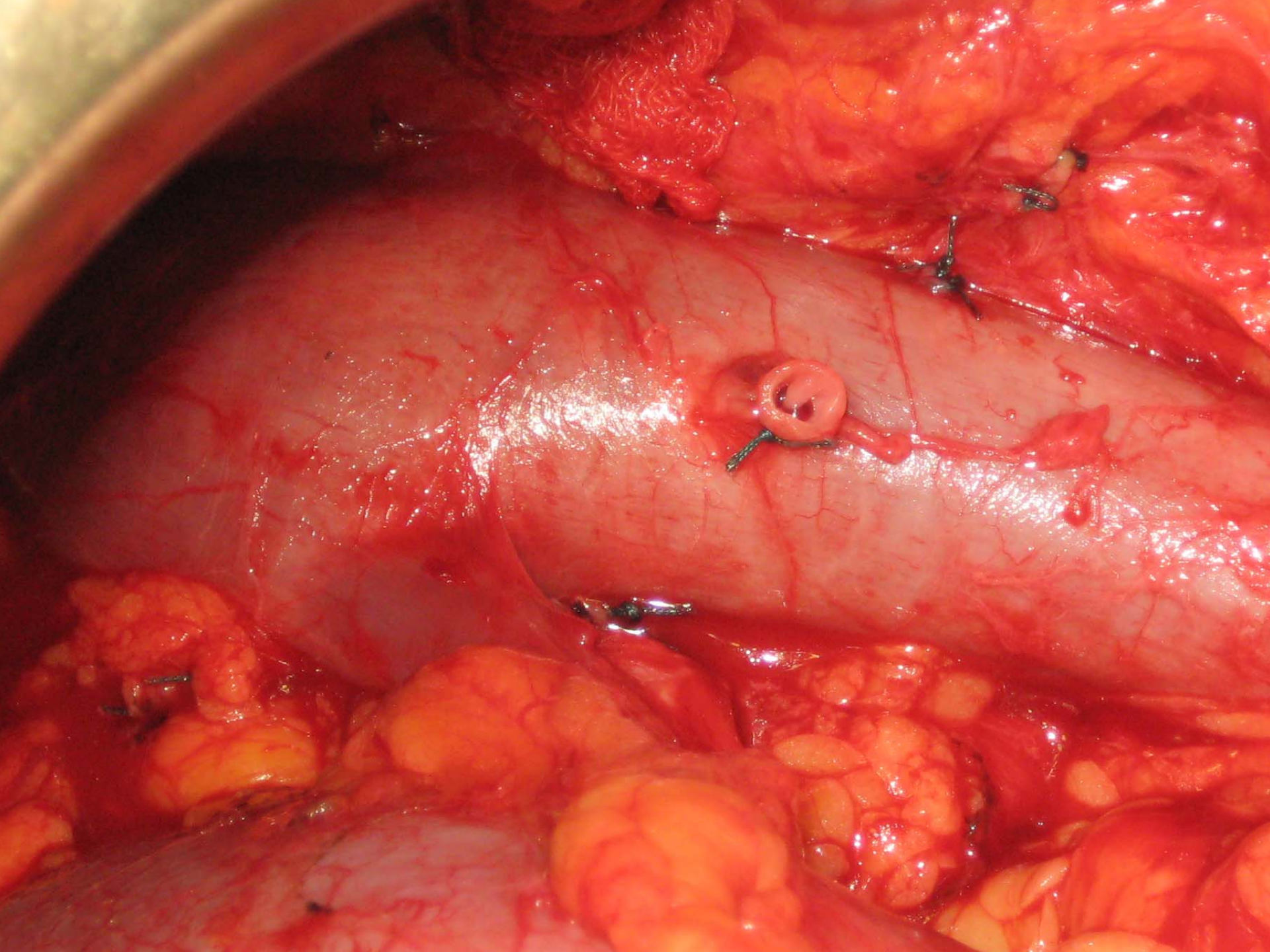


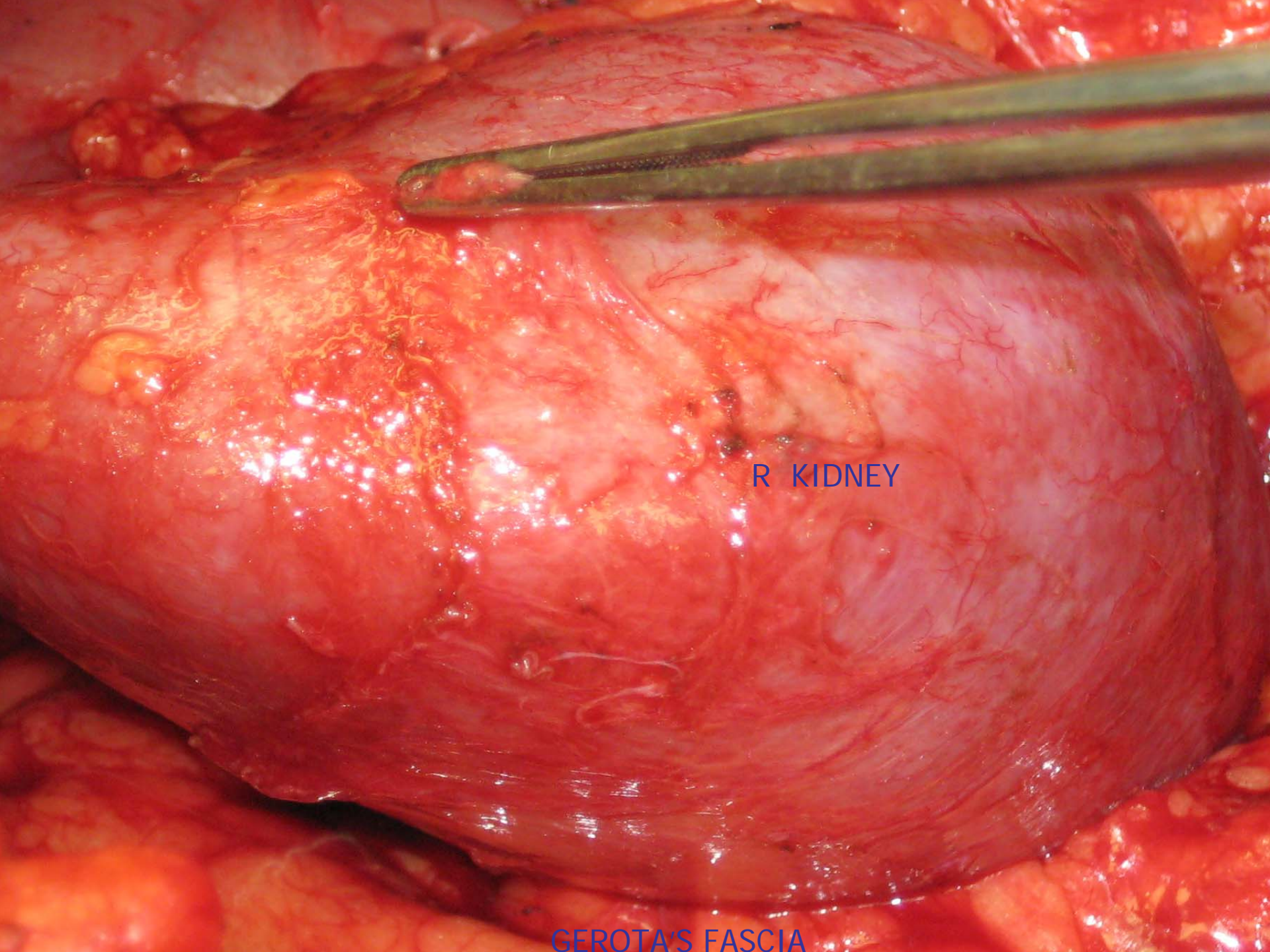


IVC

RV

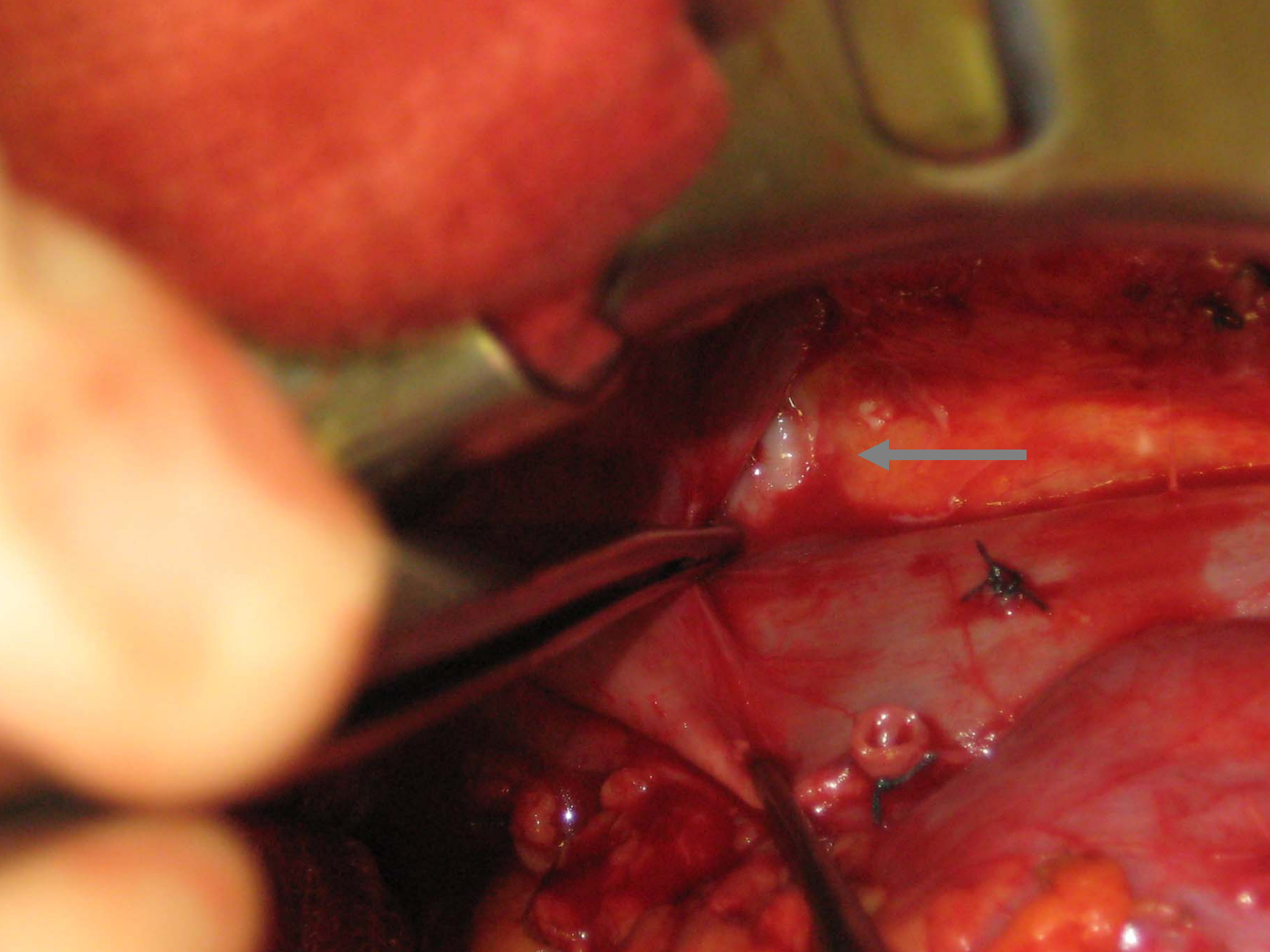
R KIDNEY

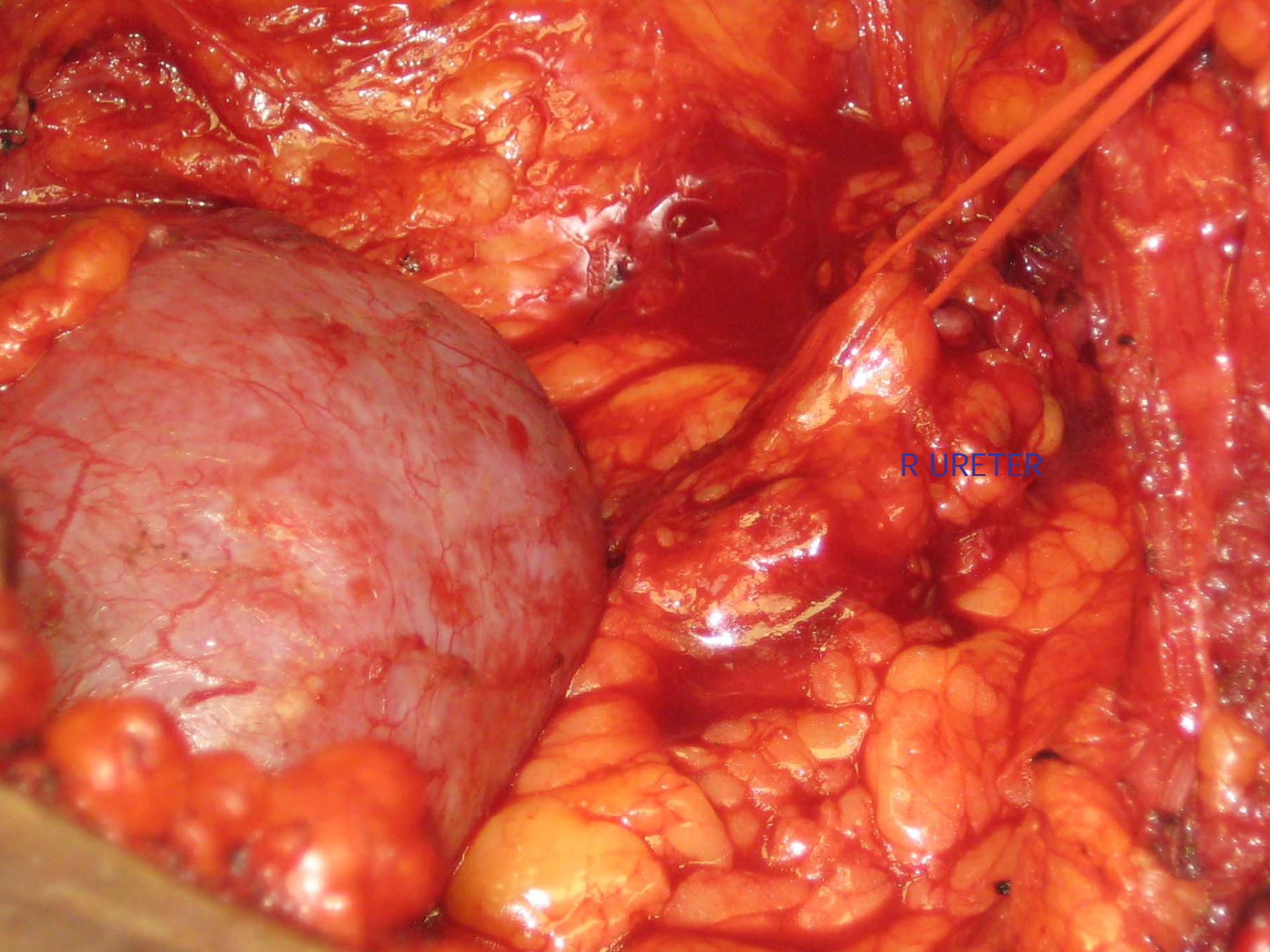




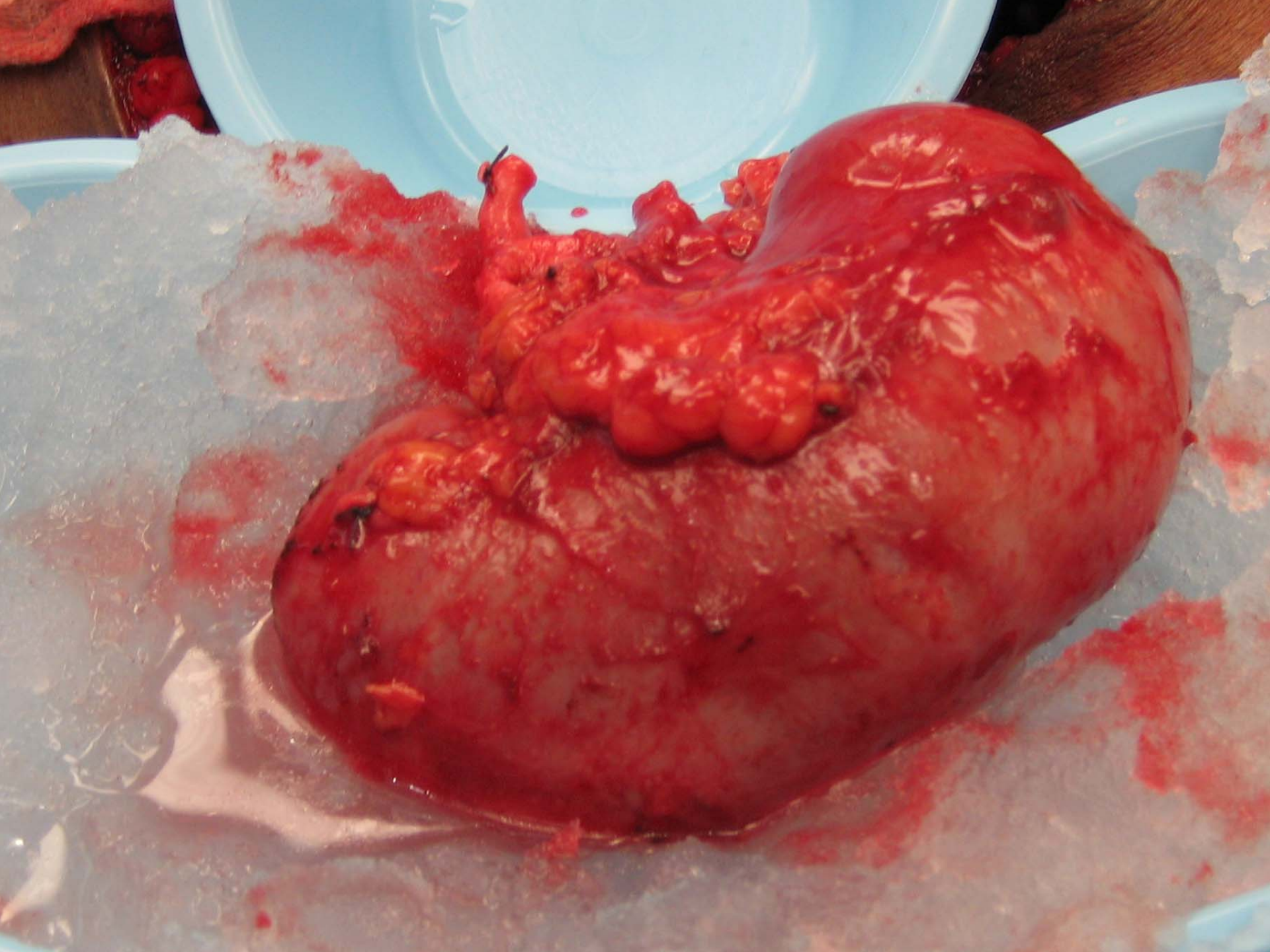
R KIDNEY

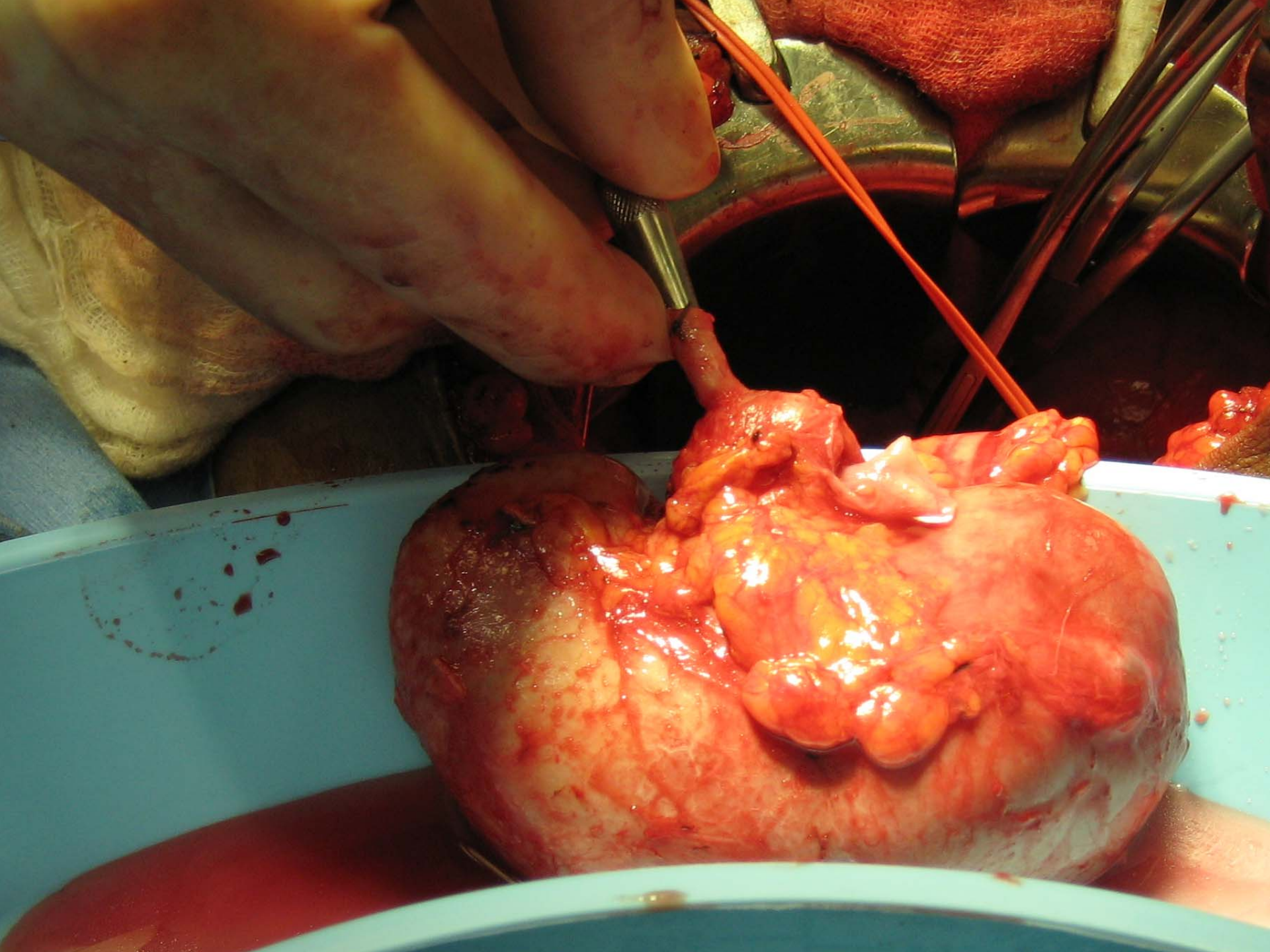
GEROTA'S FASCIA

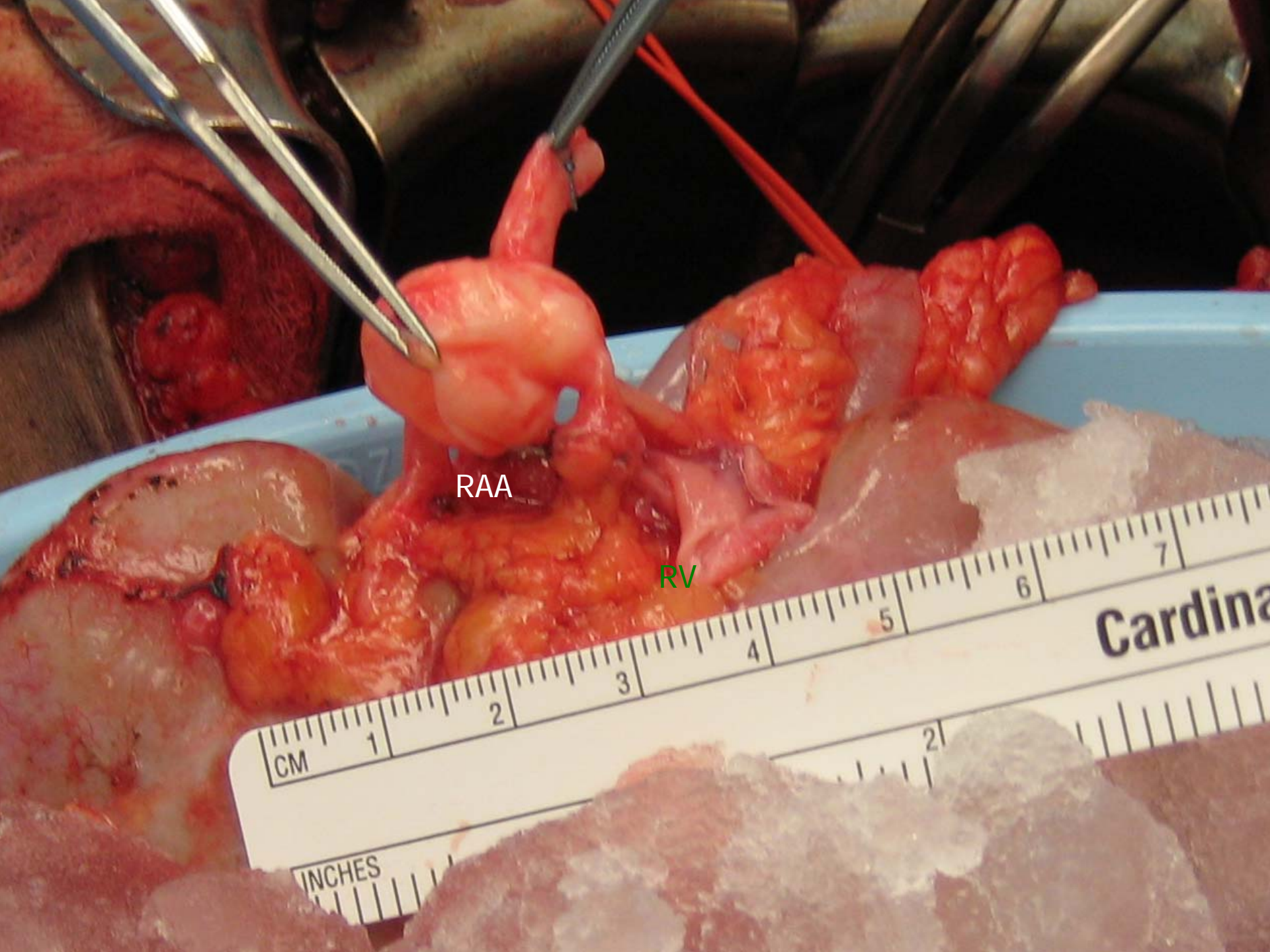




R URETER







RAA

RV

CM

1

2

3

4

5

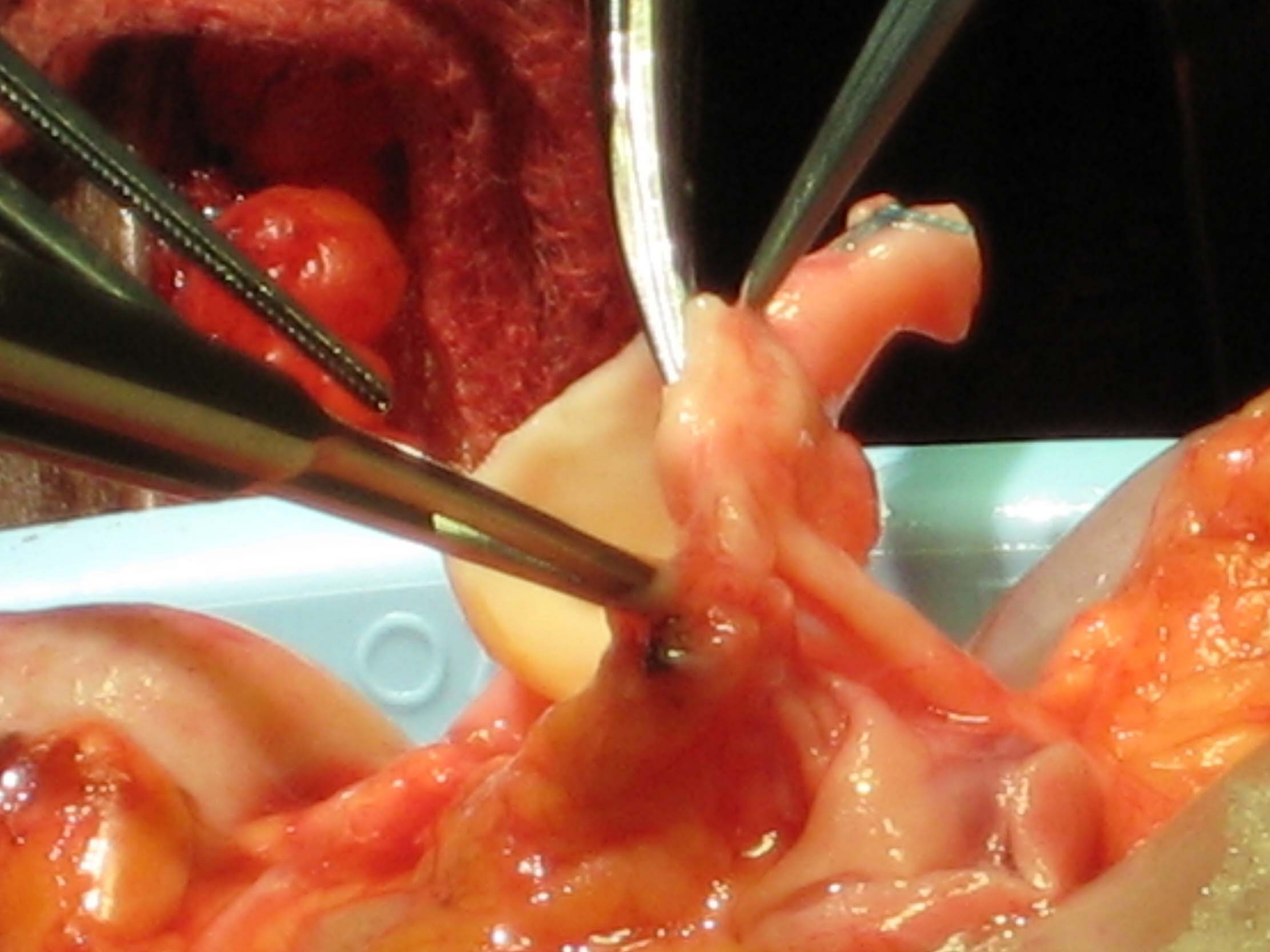
6

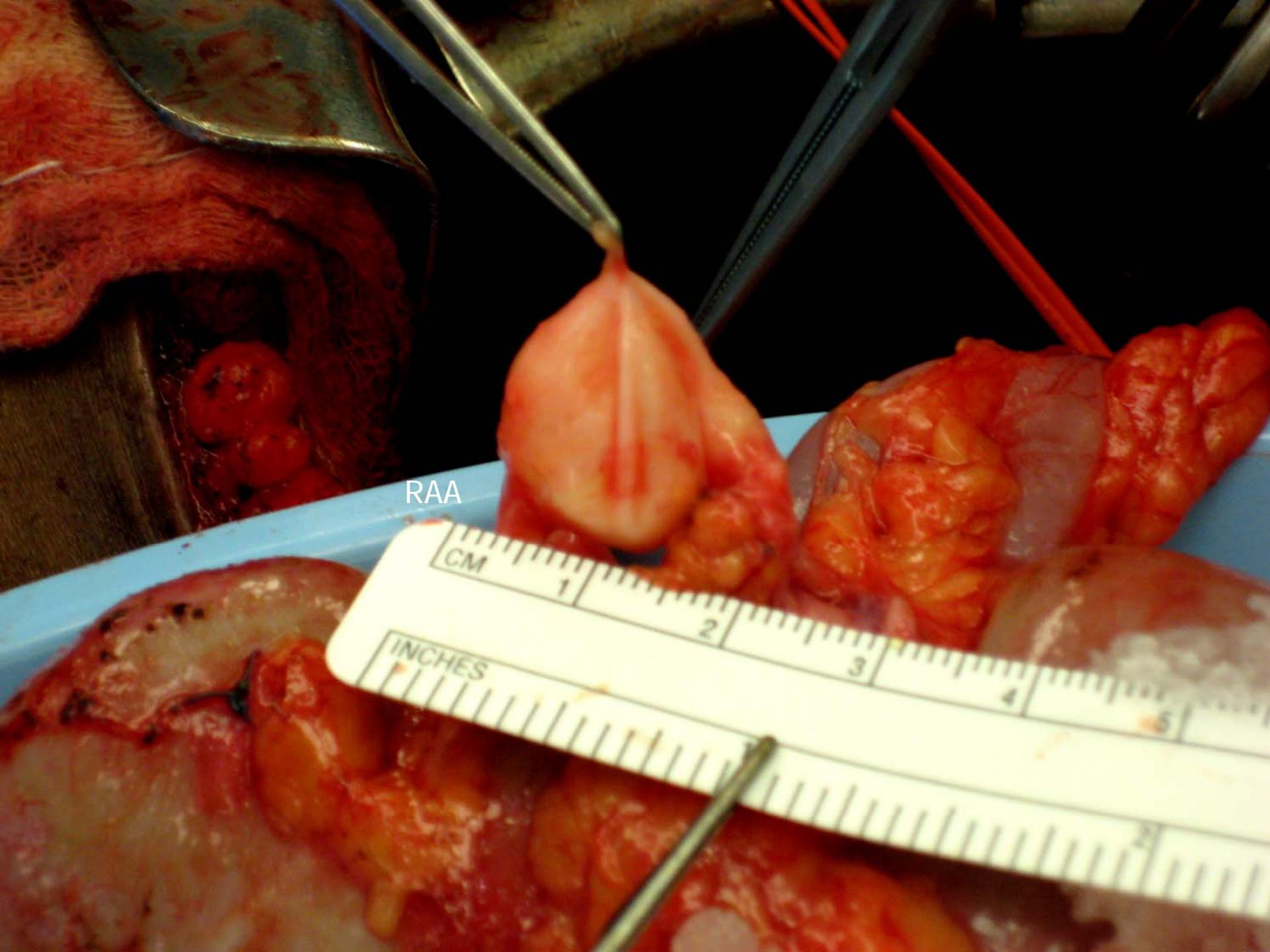
7

INCHES

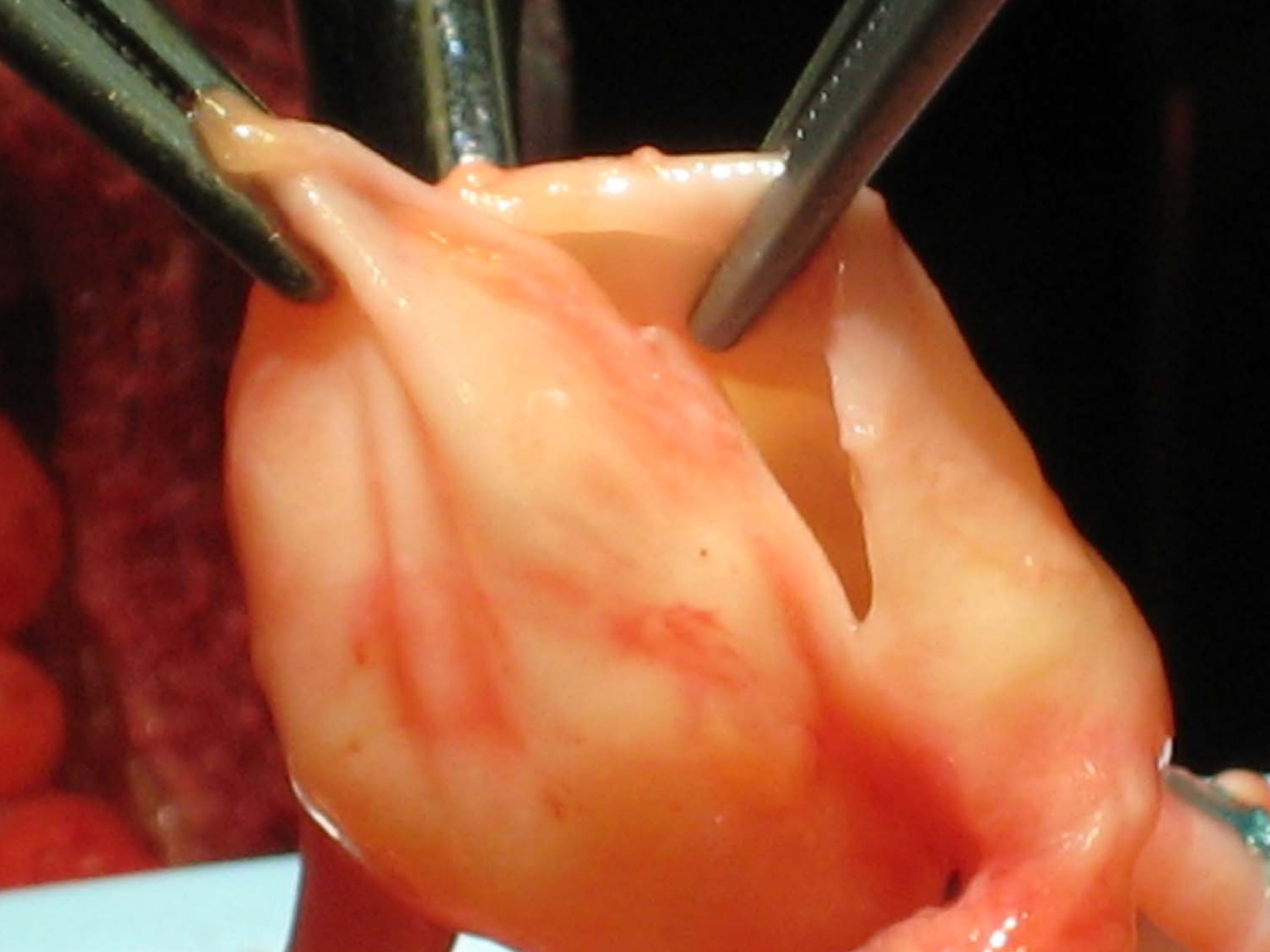
2

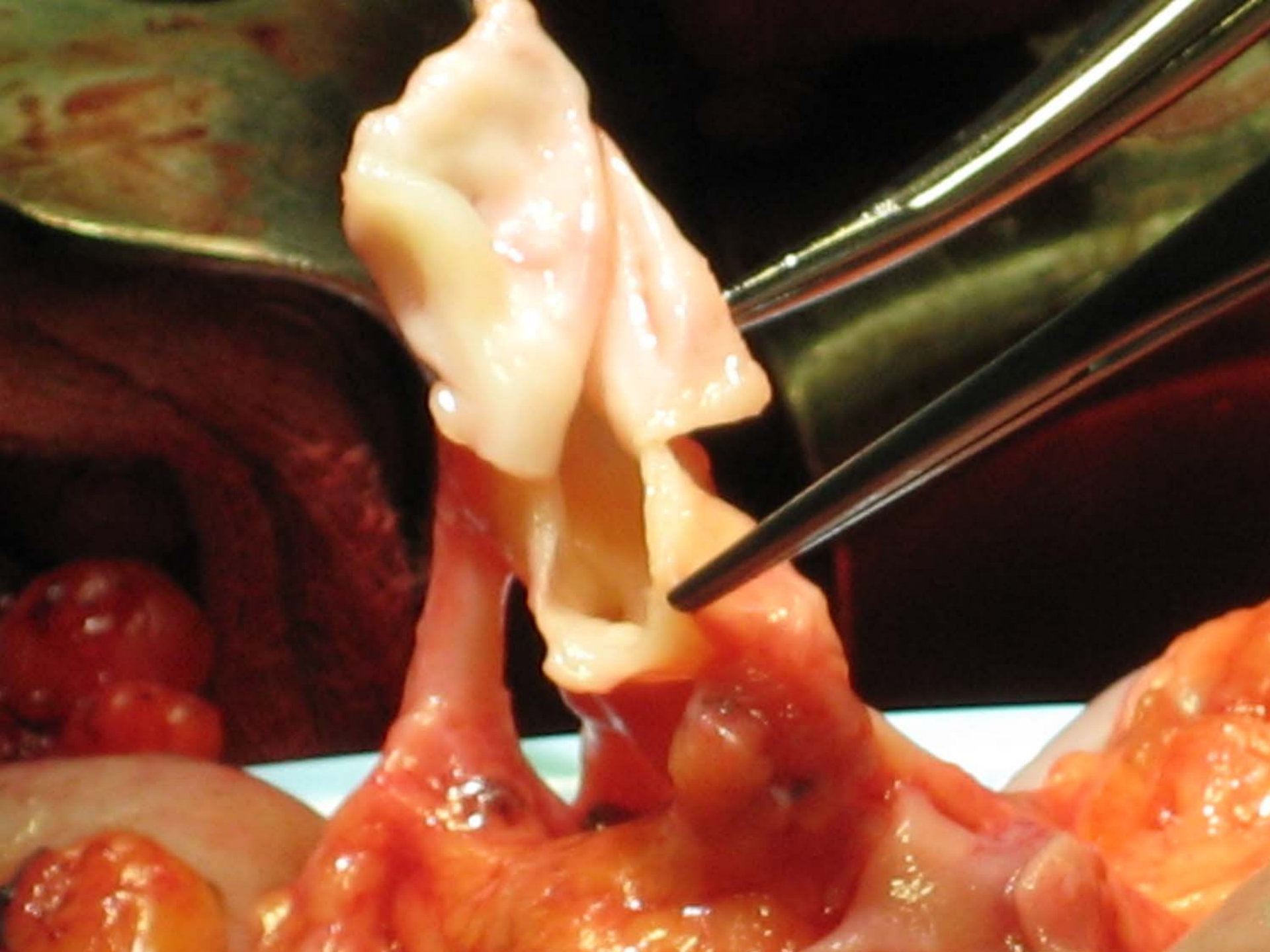
Cardinal

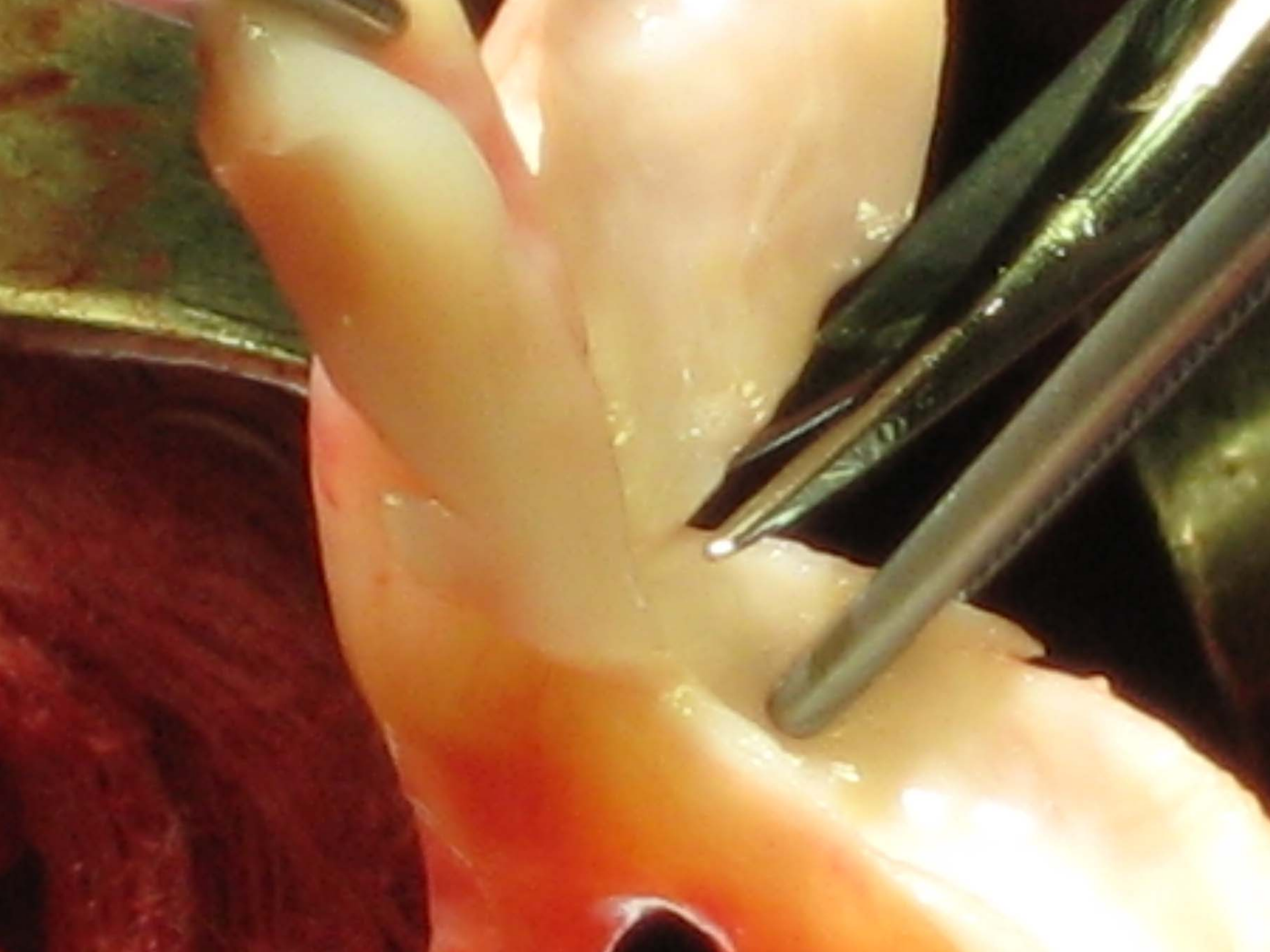


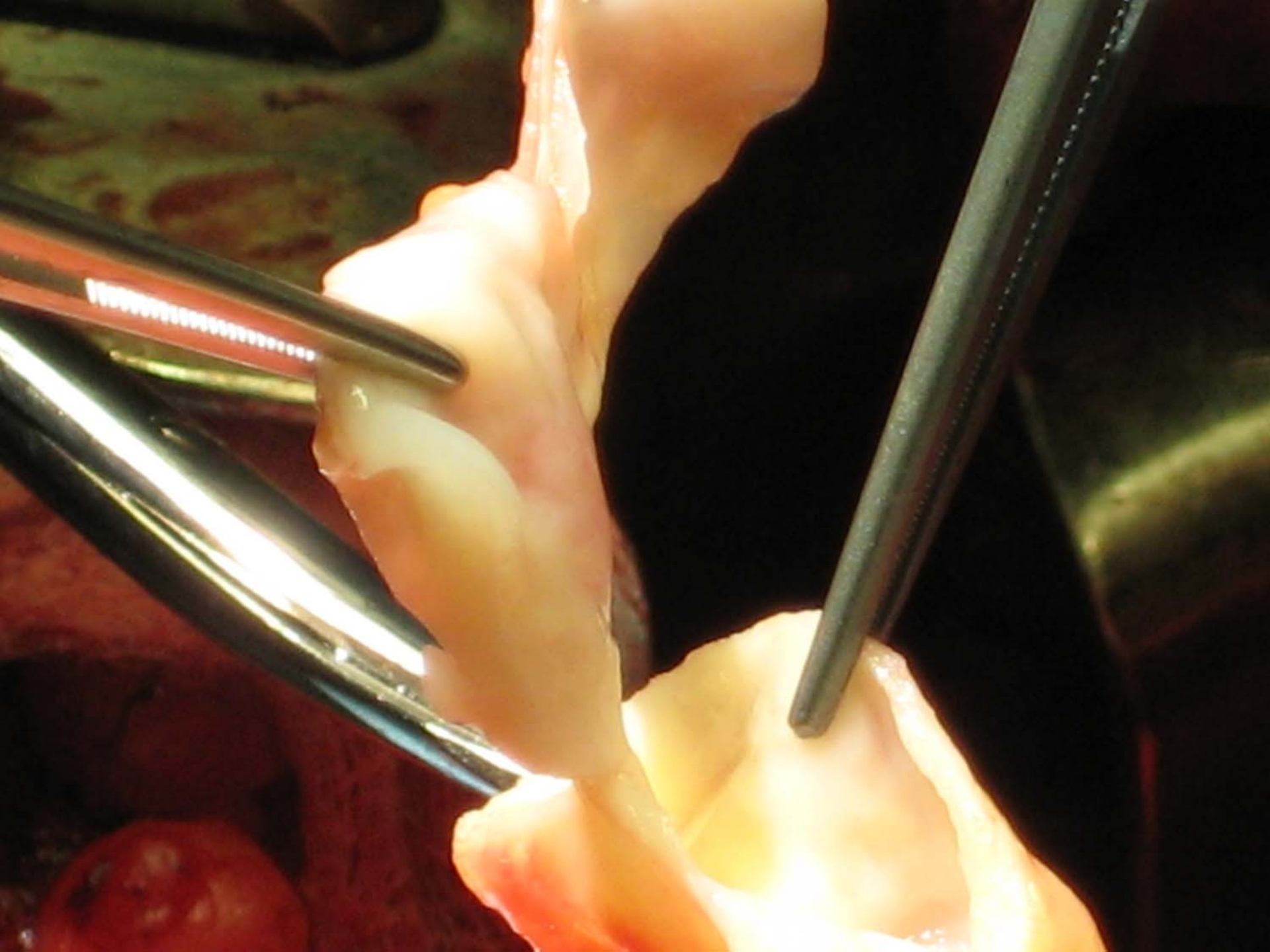


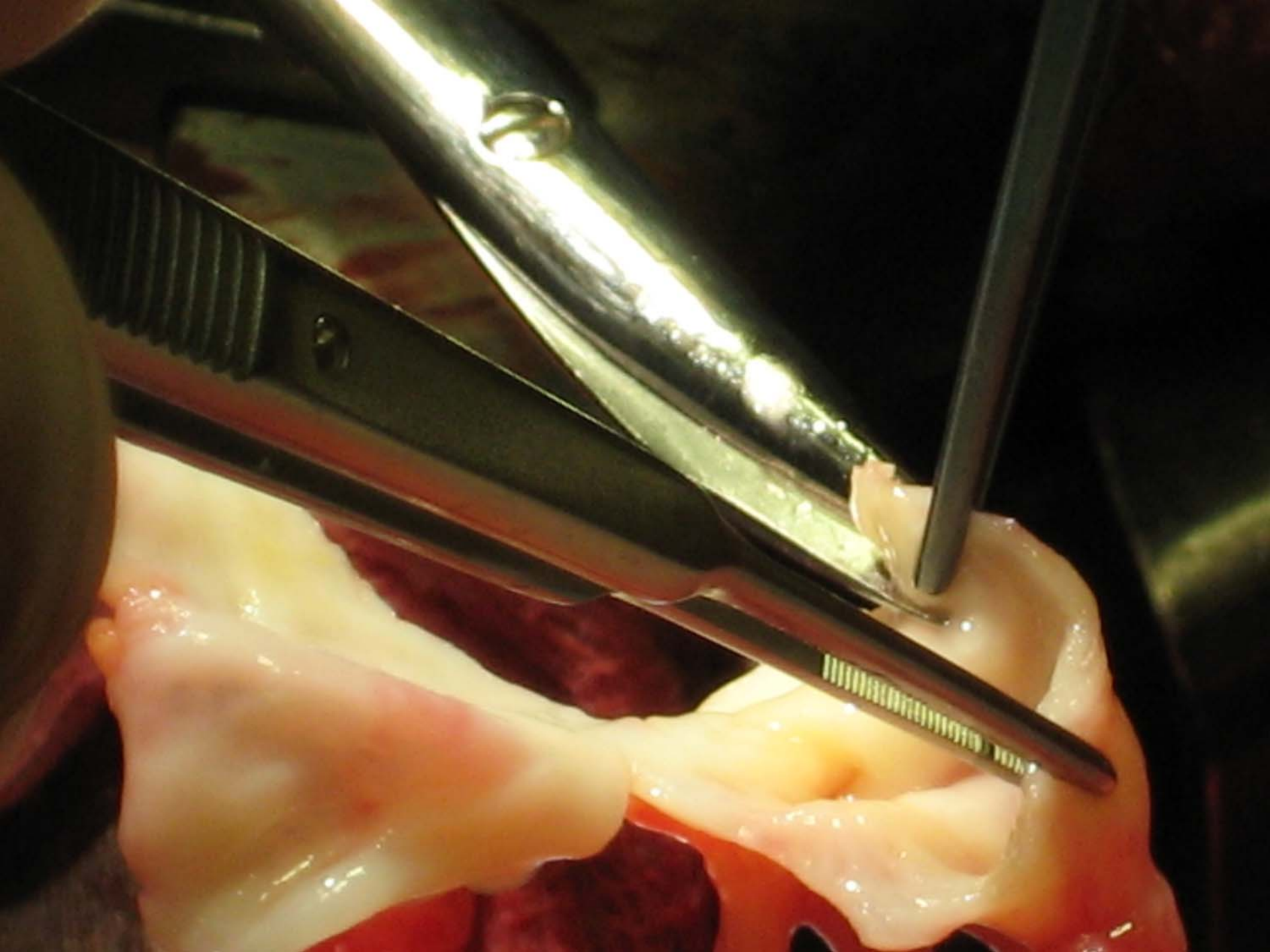
RAA

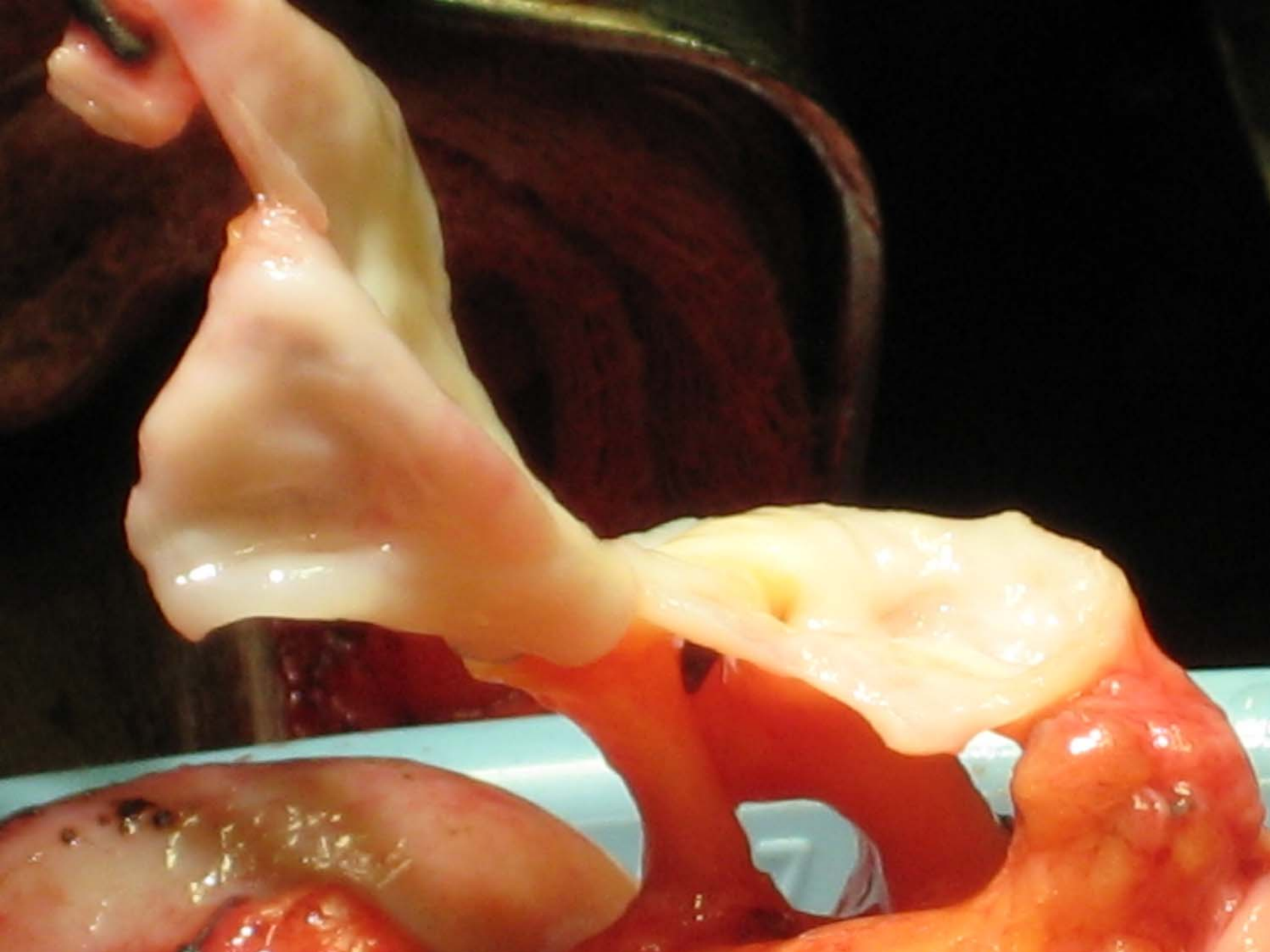


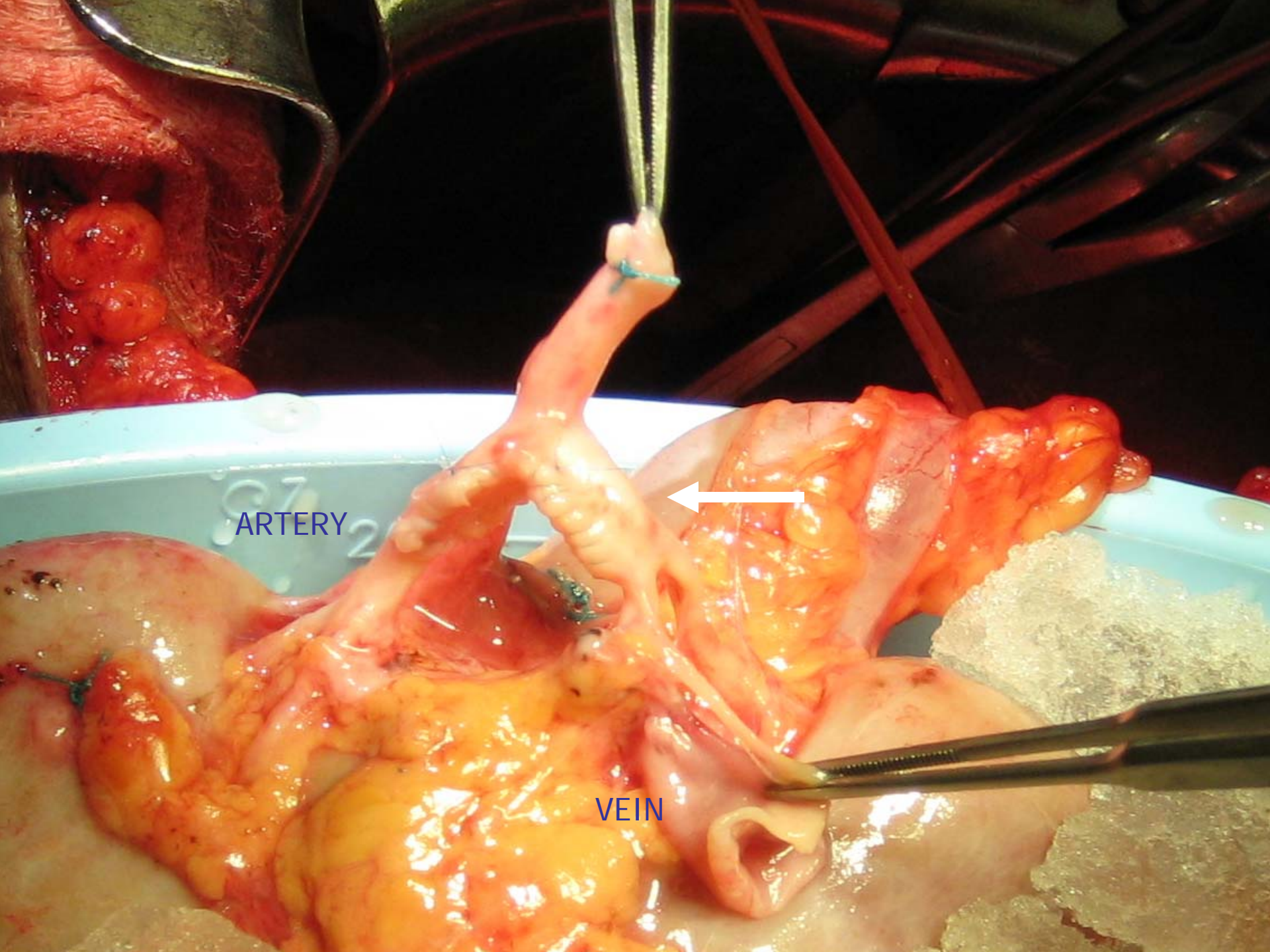






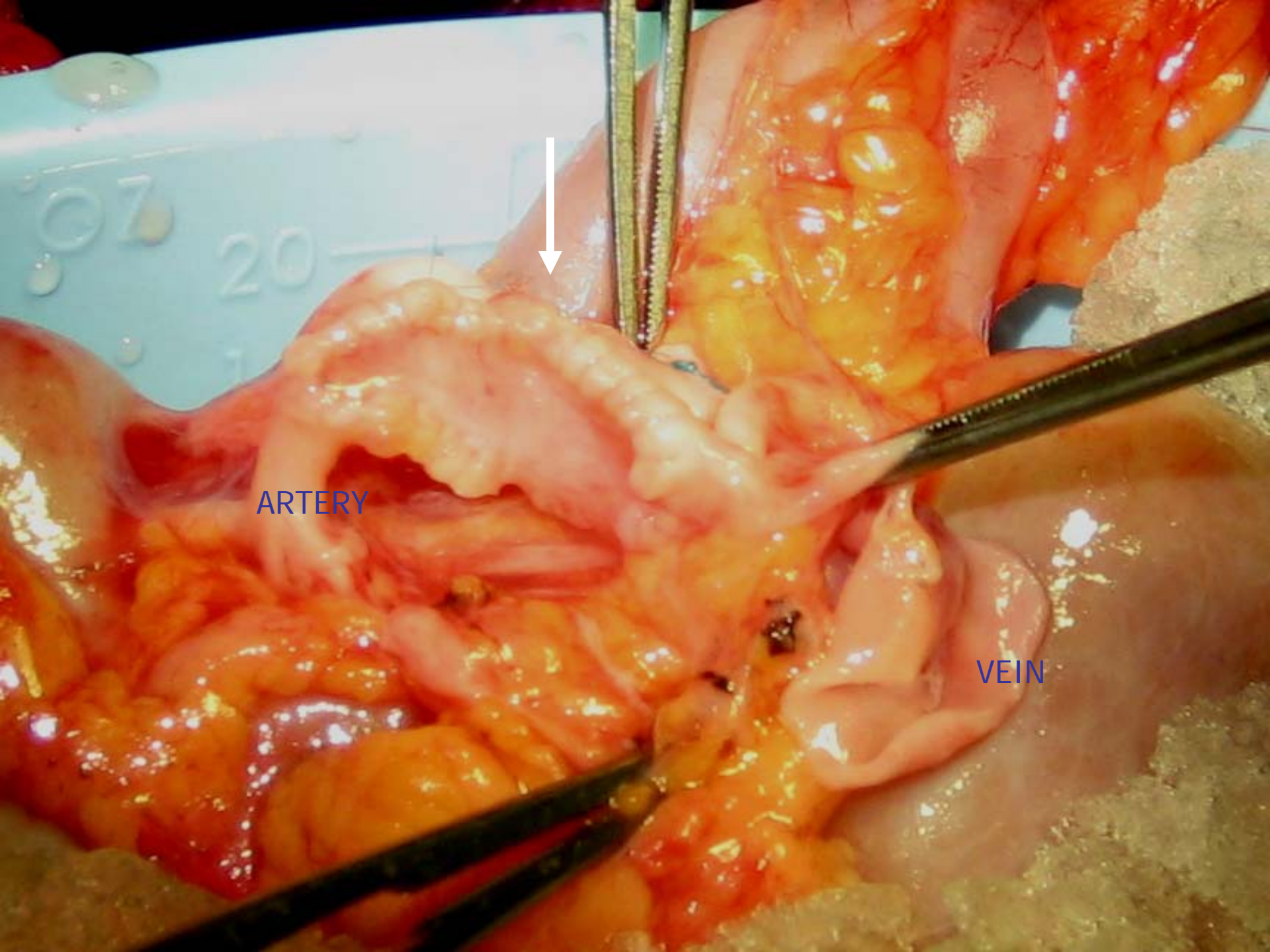






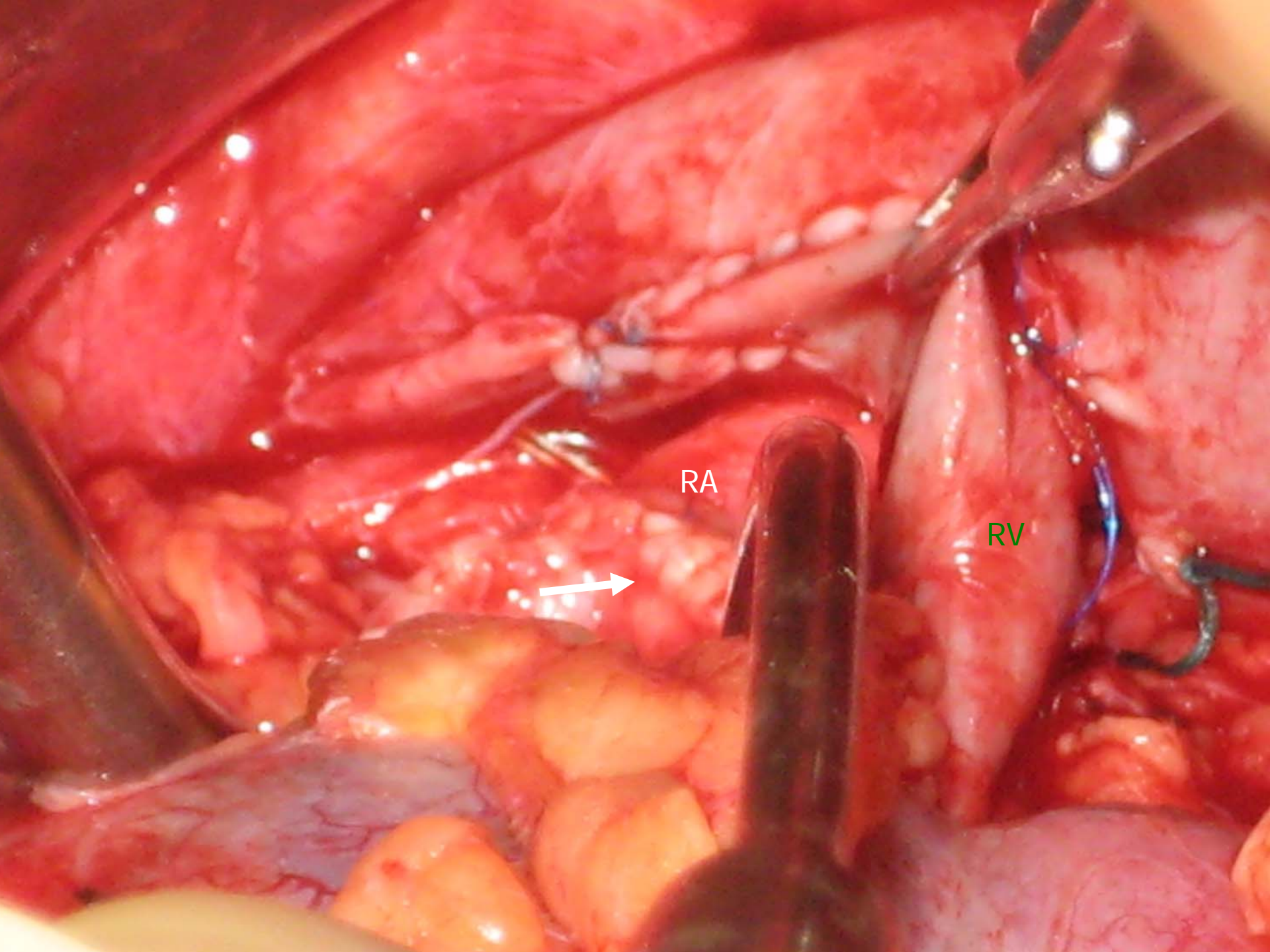
ARTERY

VEIN



ARTERY

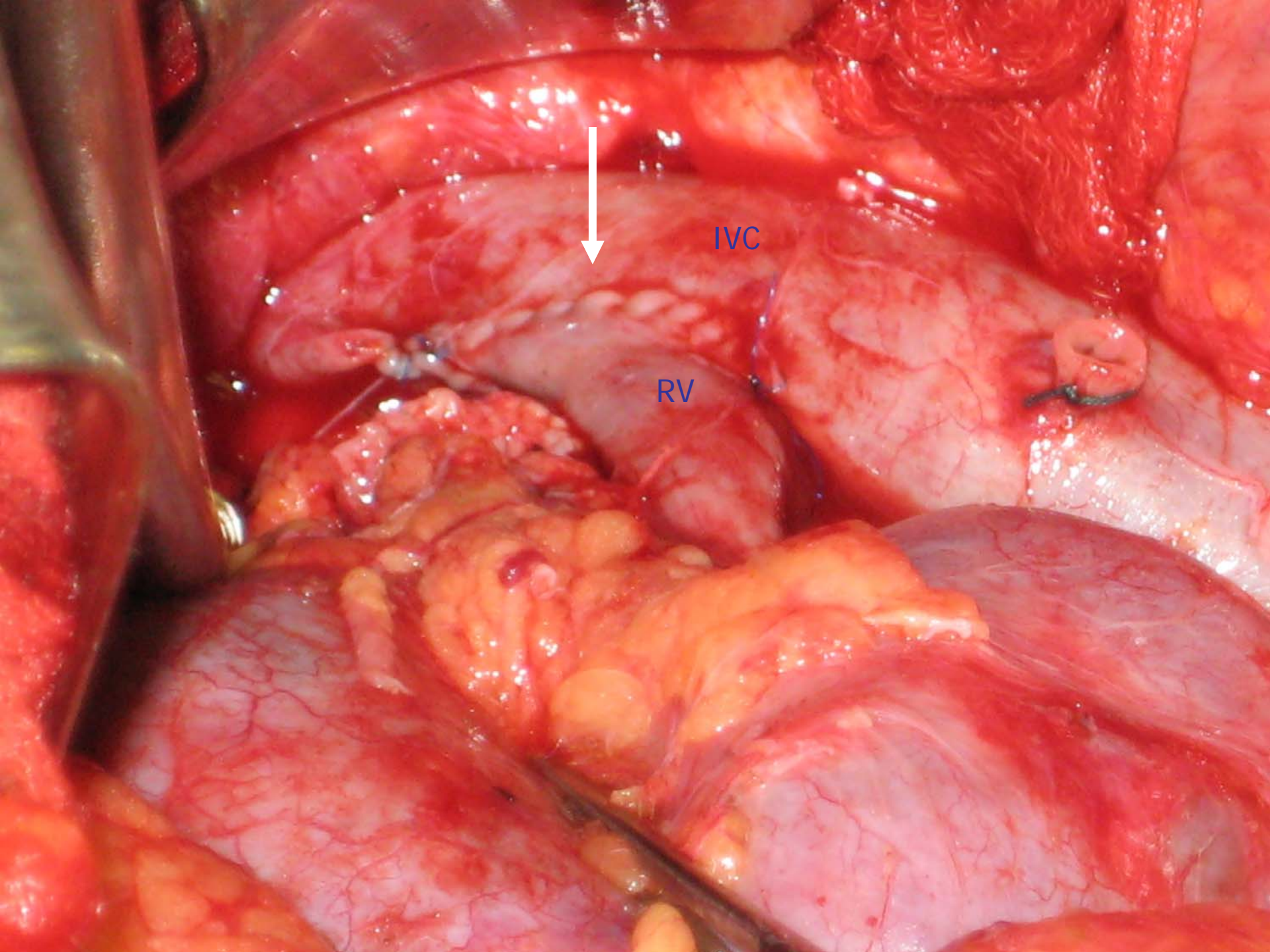
VEIN



RA

RV





IVC

RV